

ThinPrep[®]-morfologie

Afwijkingen in epitheelcellen

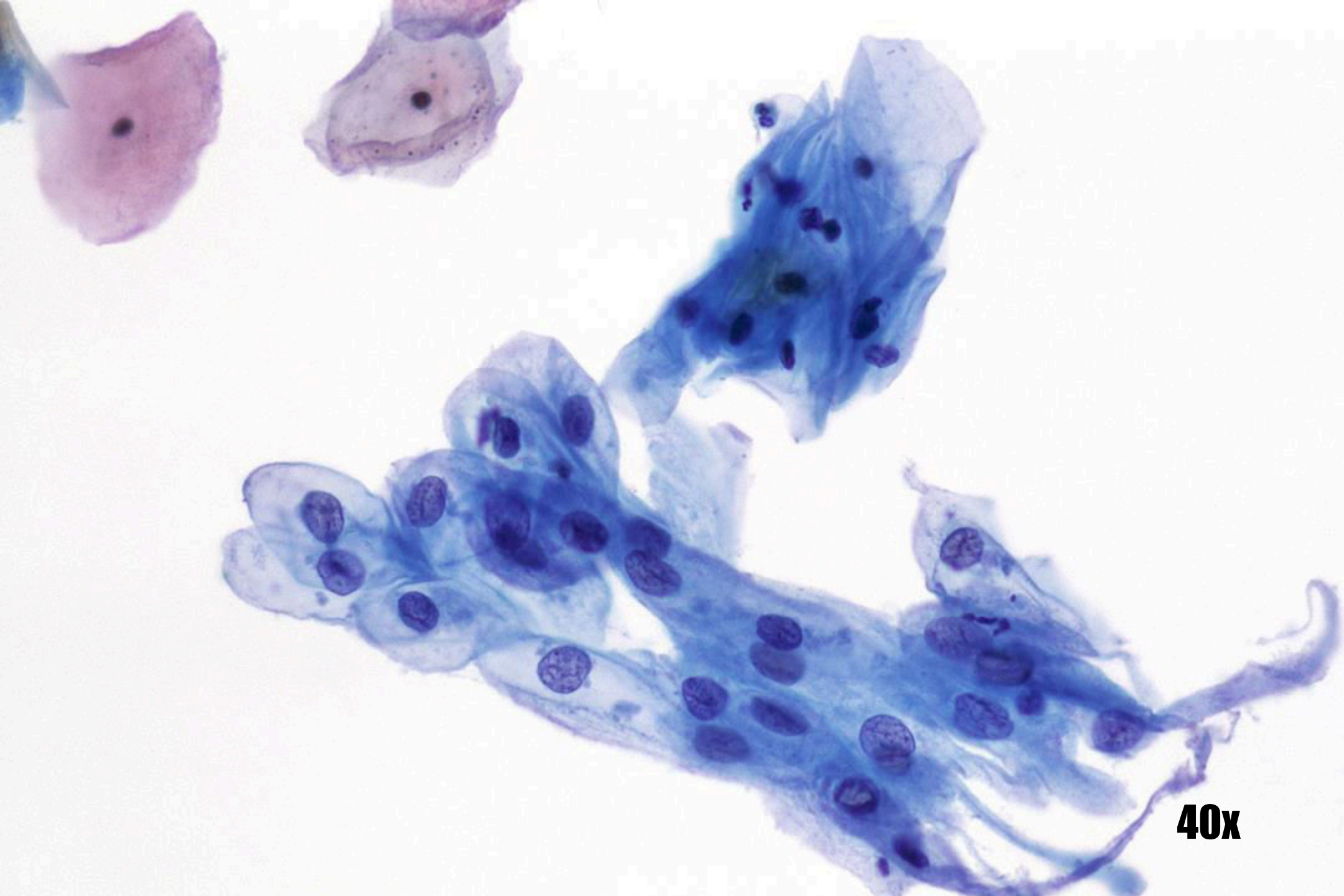
ThinPrep[®]-kenmerken

- In vloeistof fixatie
- Celgrootte
- Uitstrijkpatroon
- Achtergrond van het specimen
- Overeenkomsten > verschillen

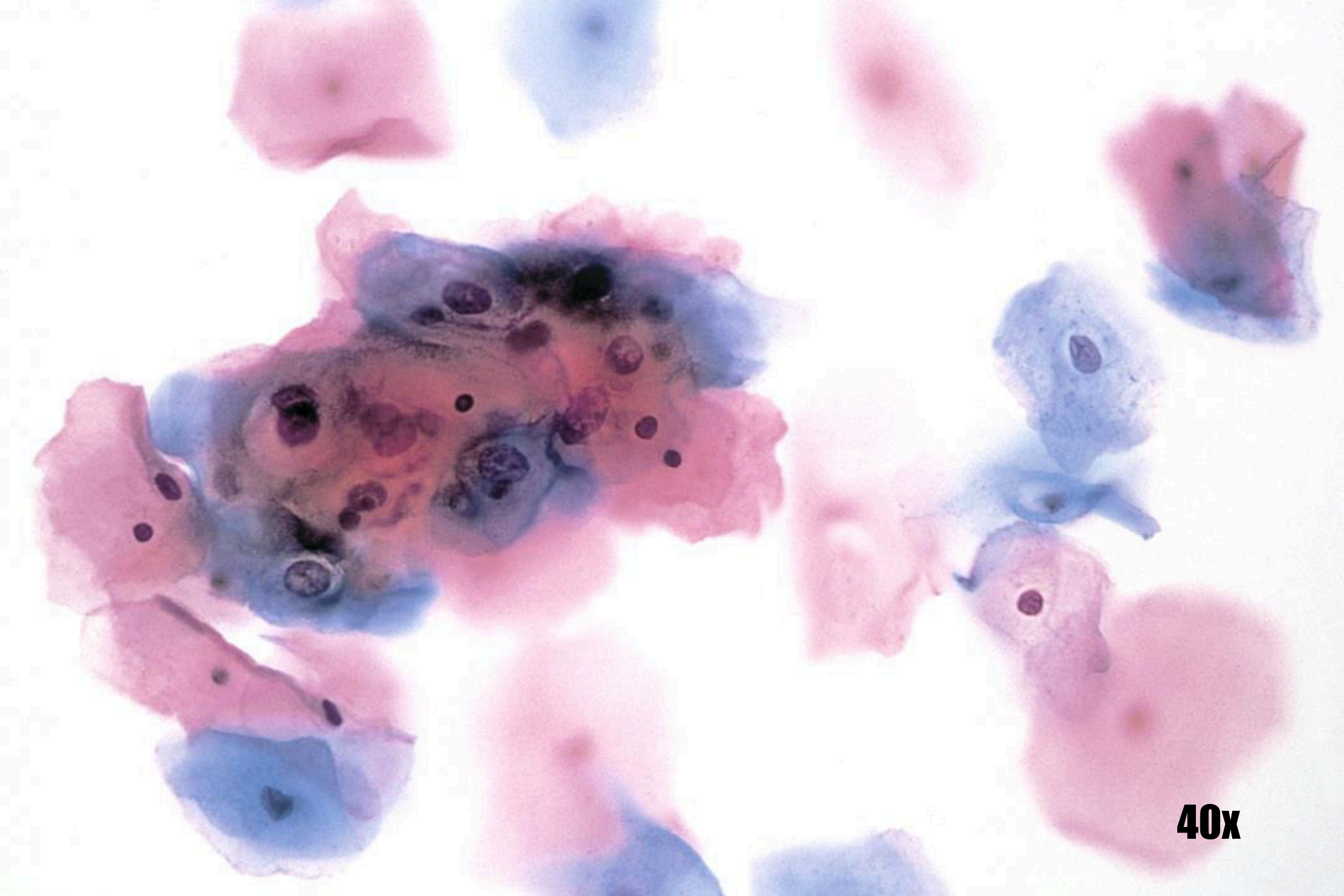
Afwijkingen in epitheelcellen - Plaveiselcellen

ASC-US

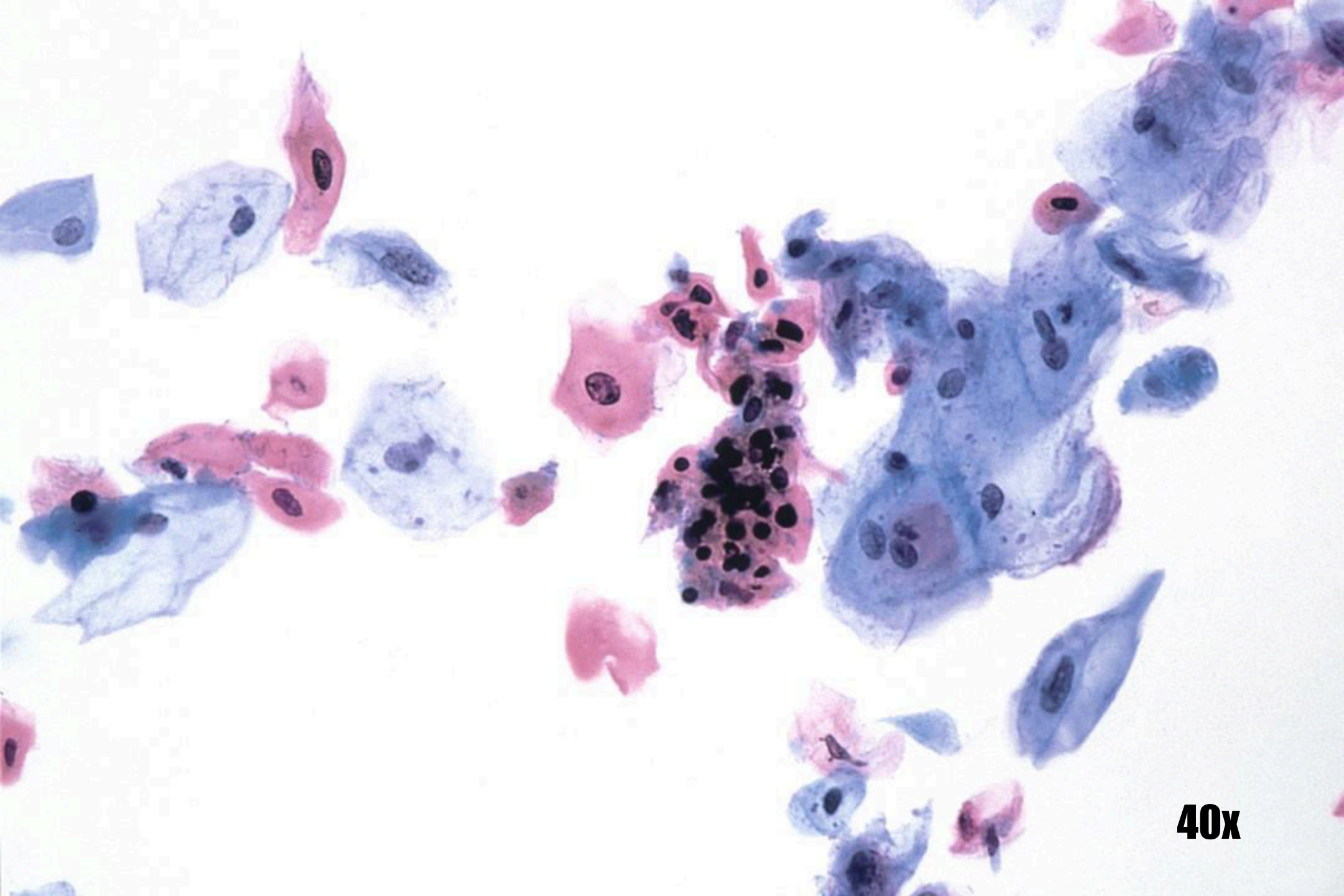
- Komen in lagen of als enkele cellen voor
- Kernen 2,5-3x intermediaire kern
- Uniforme chromatineverdeling
- Minder artefacten in preparaat



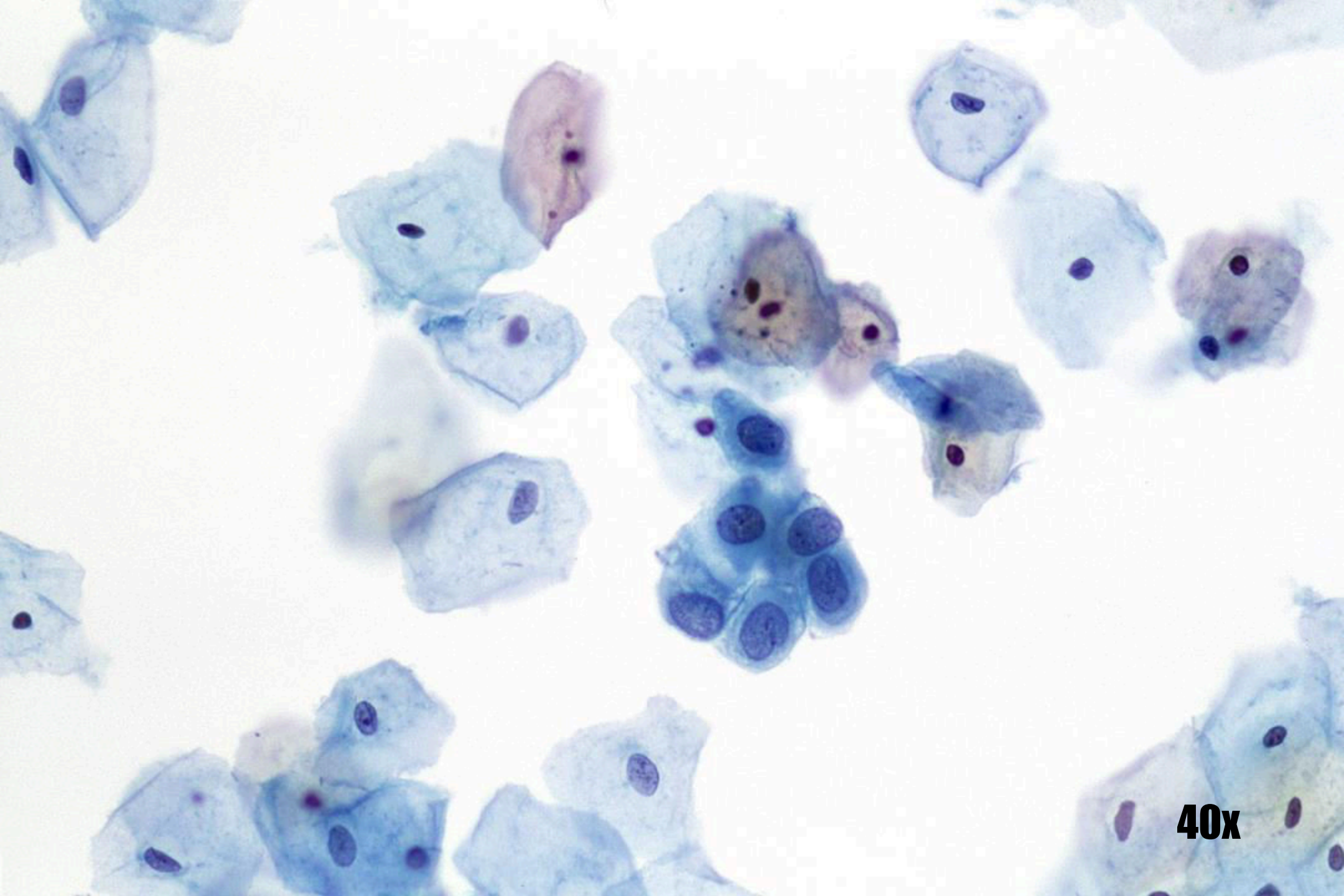
40x



40x



40x

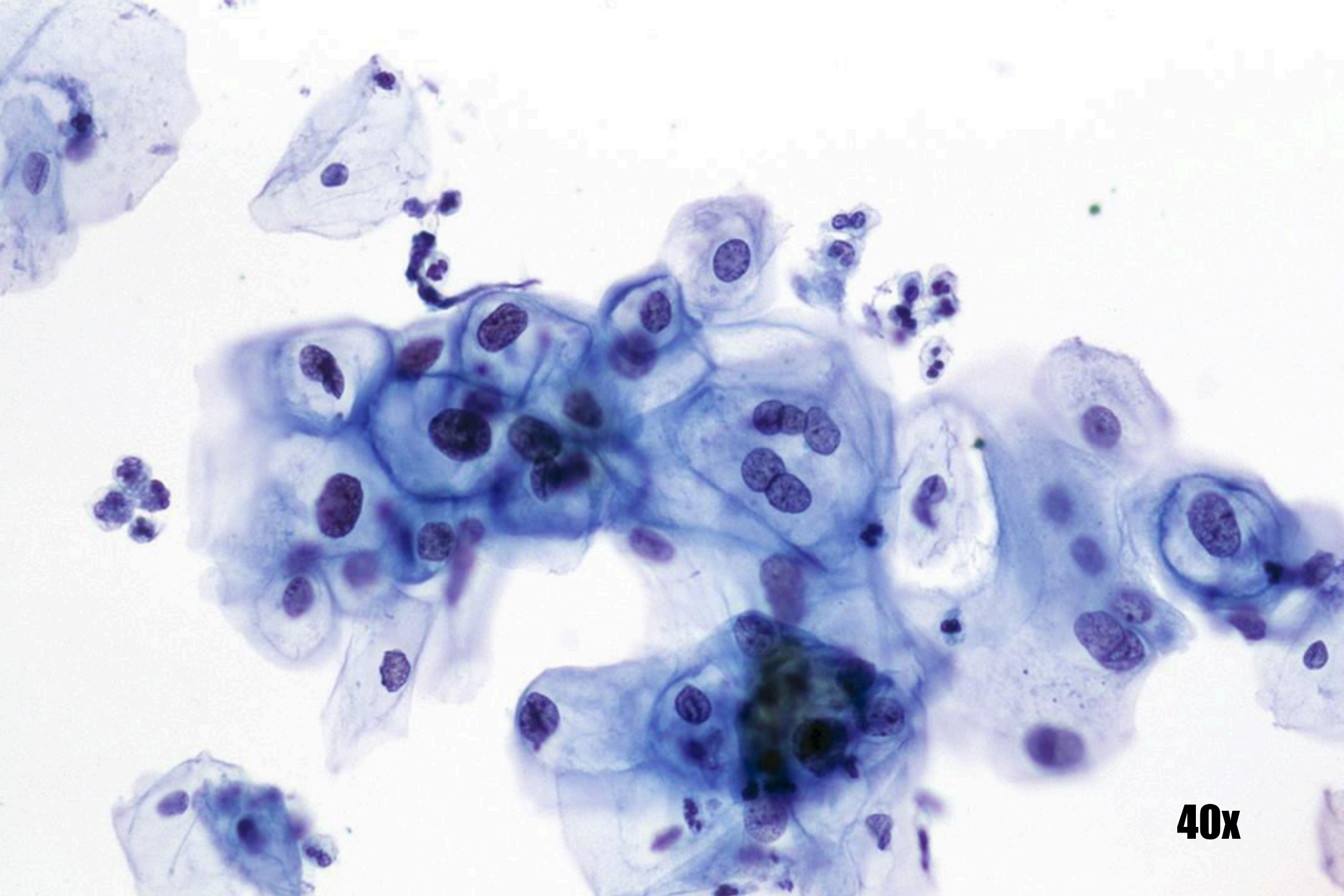


40x

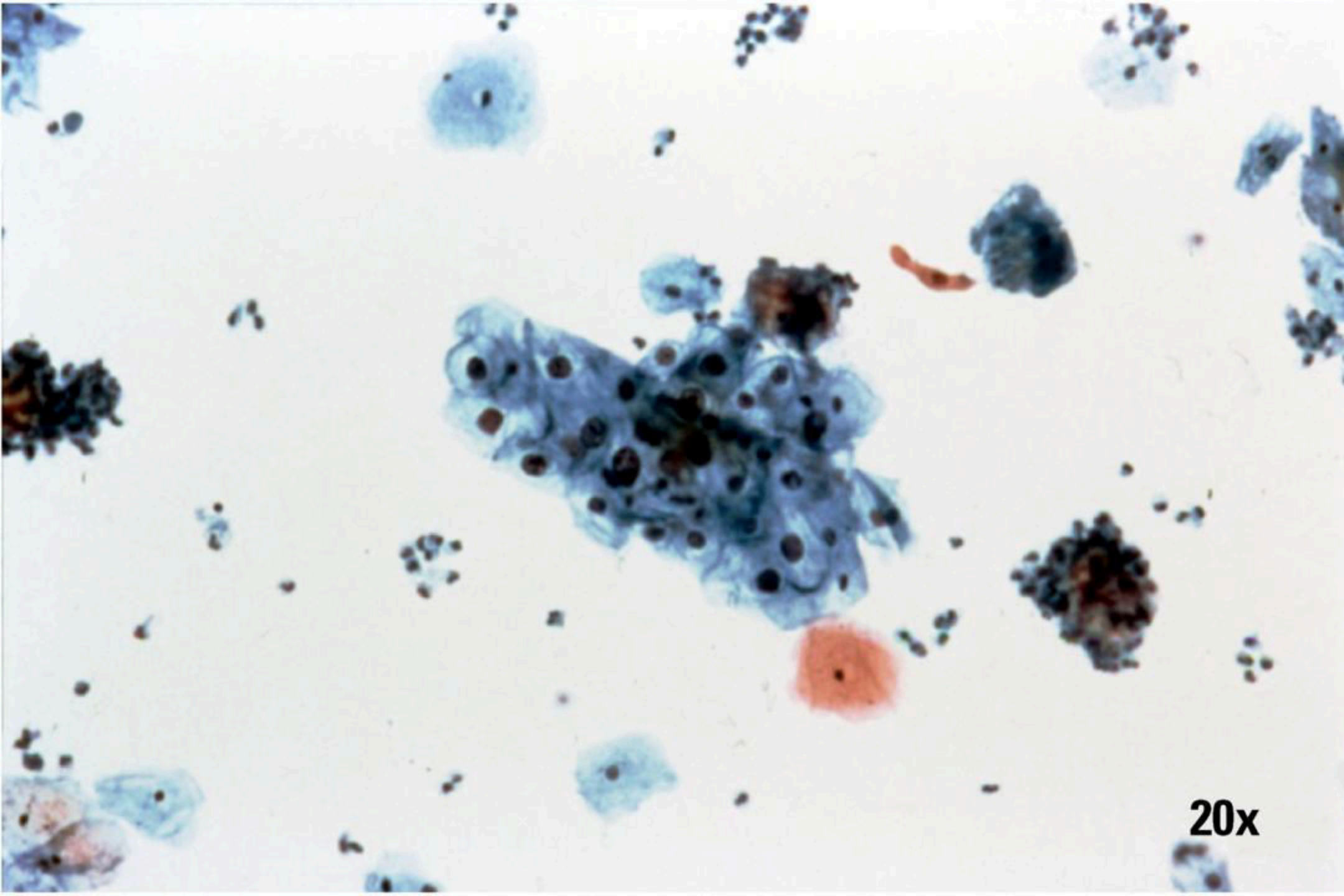
Afwijkingen in epitheelcellen - Plaveiselcellen

LSIL/lichte dysplasie

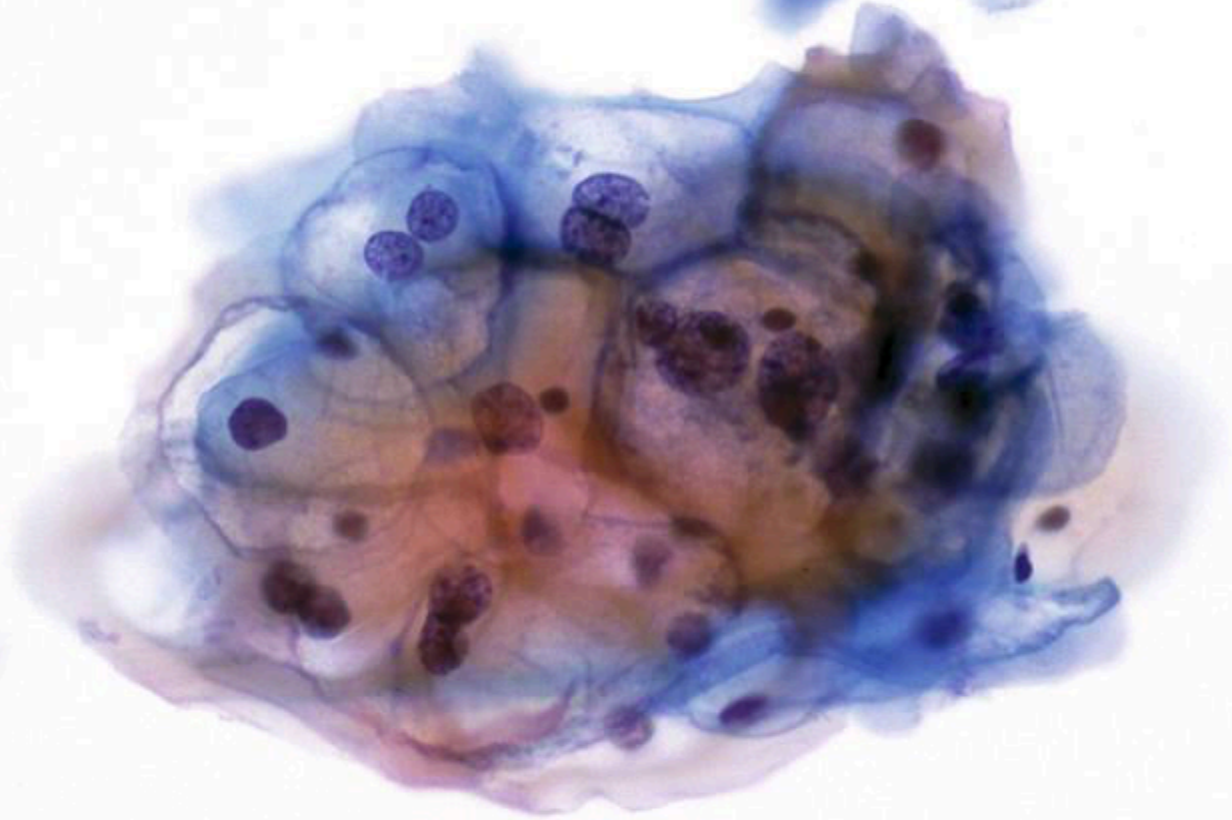
- Meer kerndetails
- Onregelmatig kernmembraan
- Kernen 3-4x intermediaire kern
- Scherpe, onregelmatige cytoplasma cavitatie (HPV-effect)



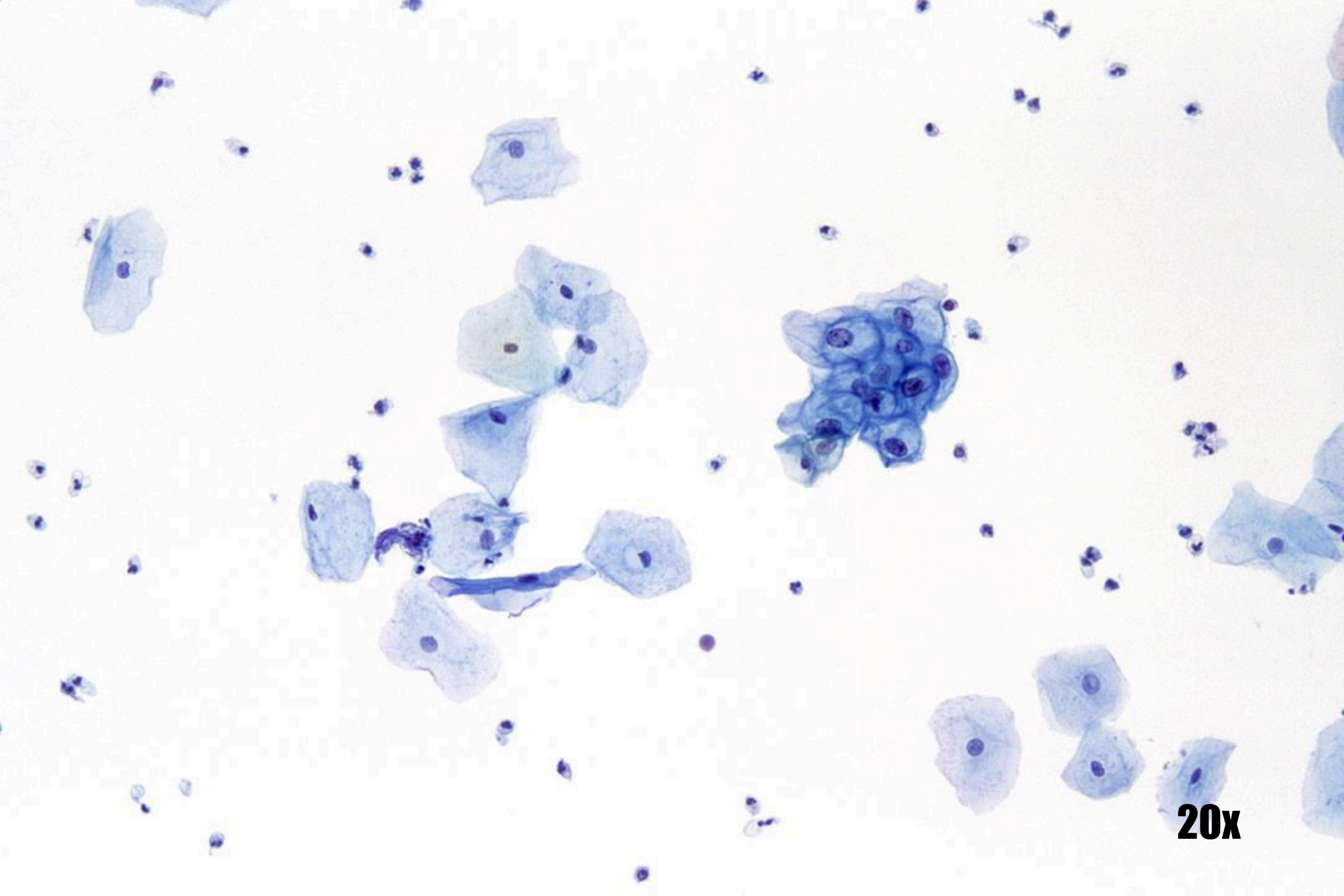
40x



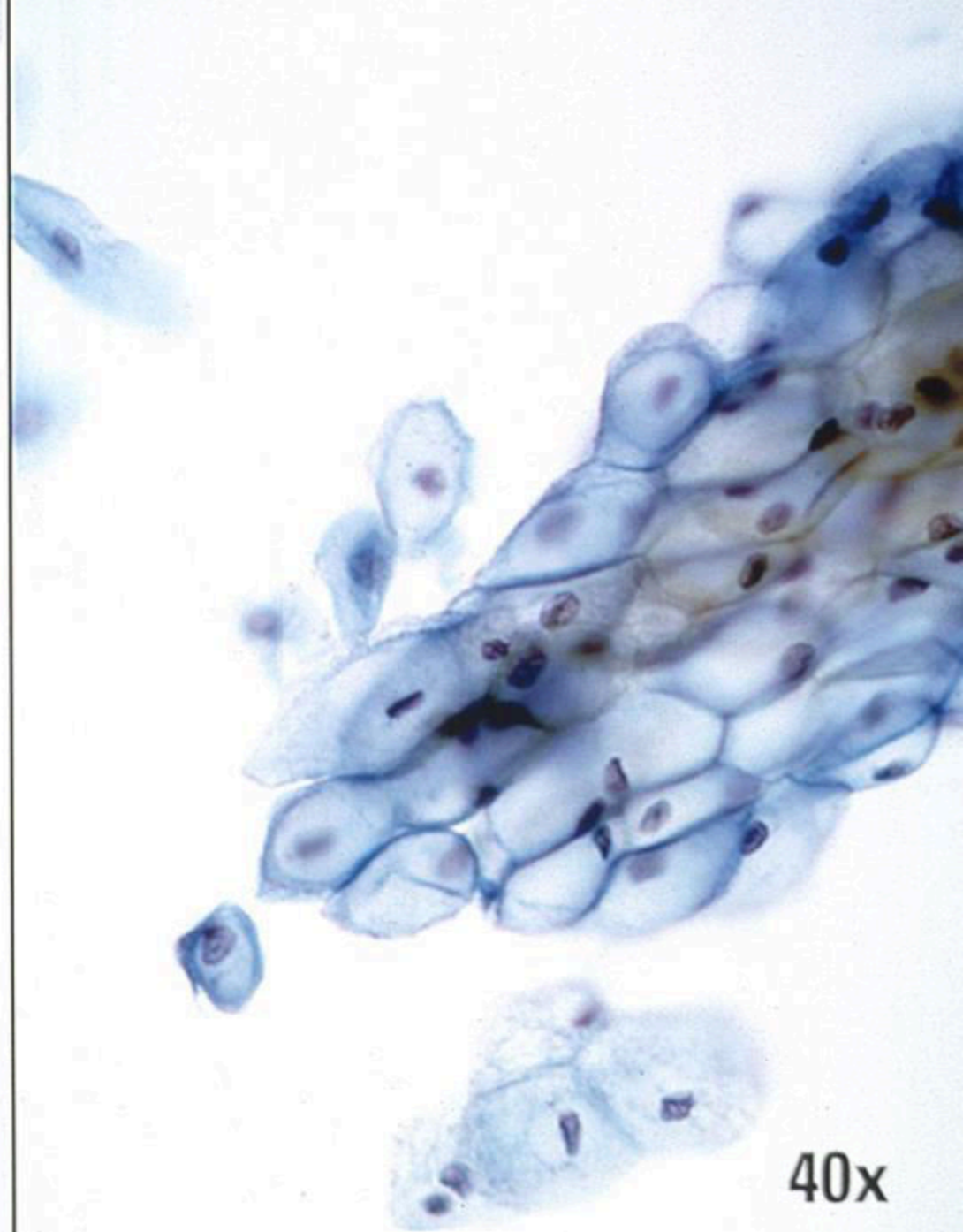
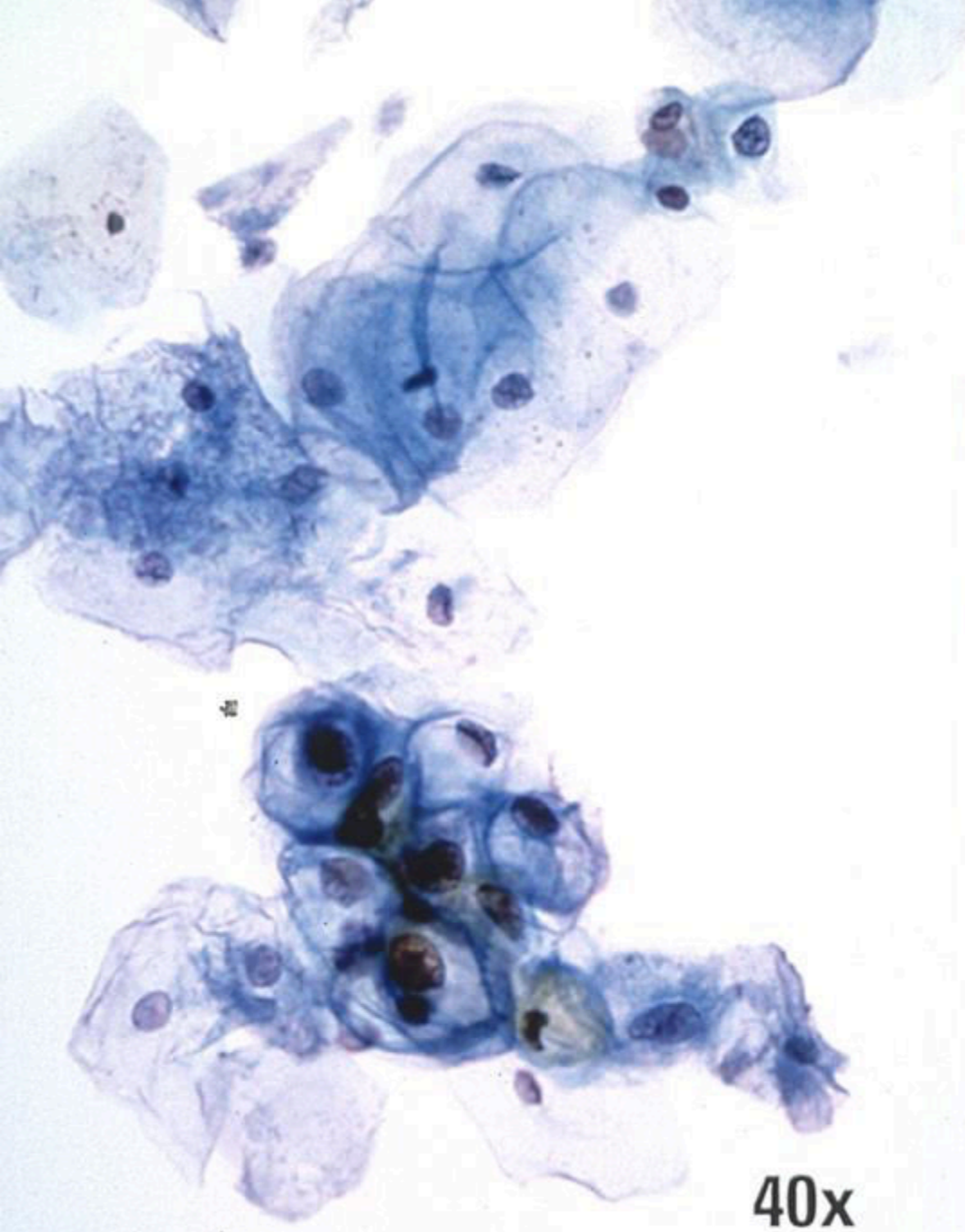
20x



40x



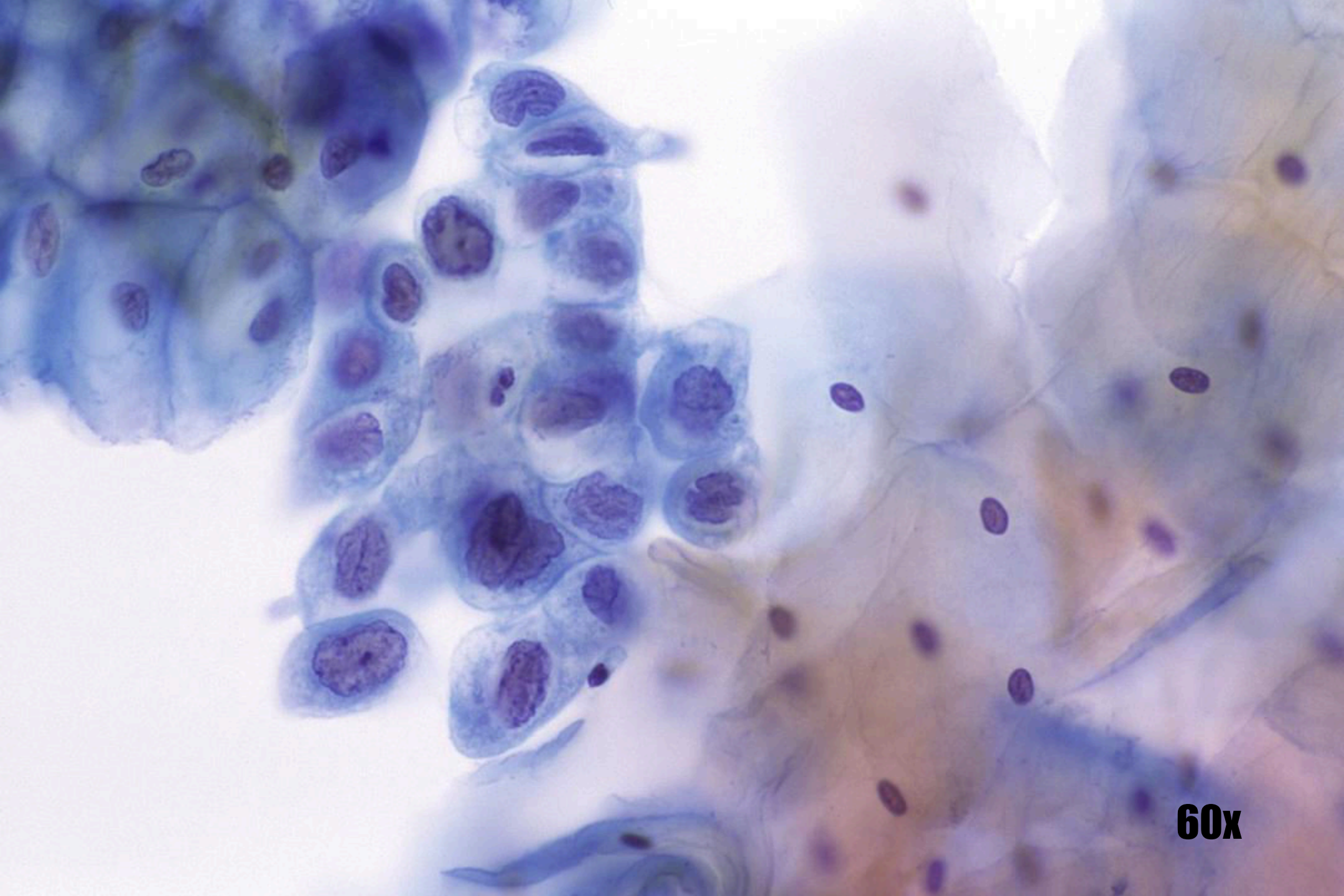
20x



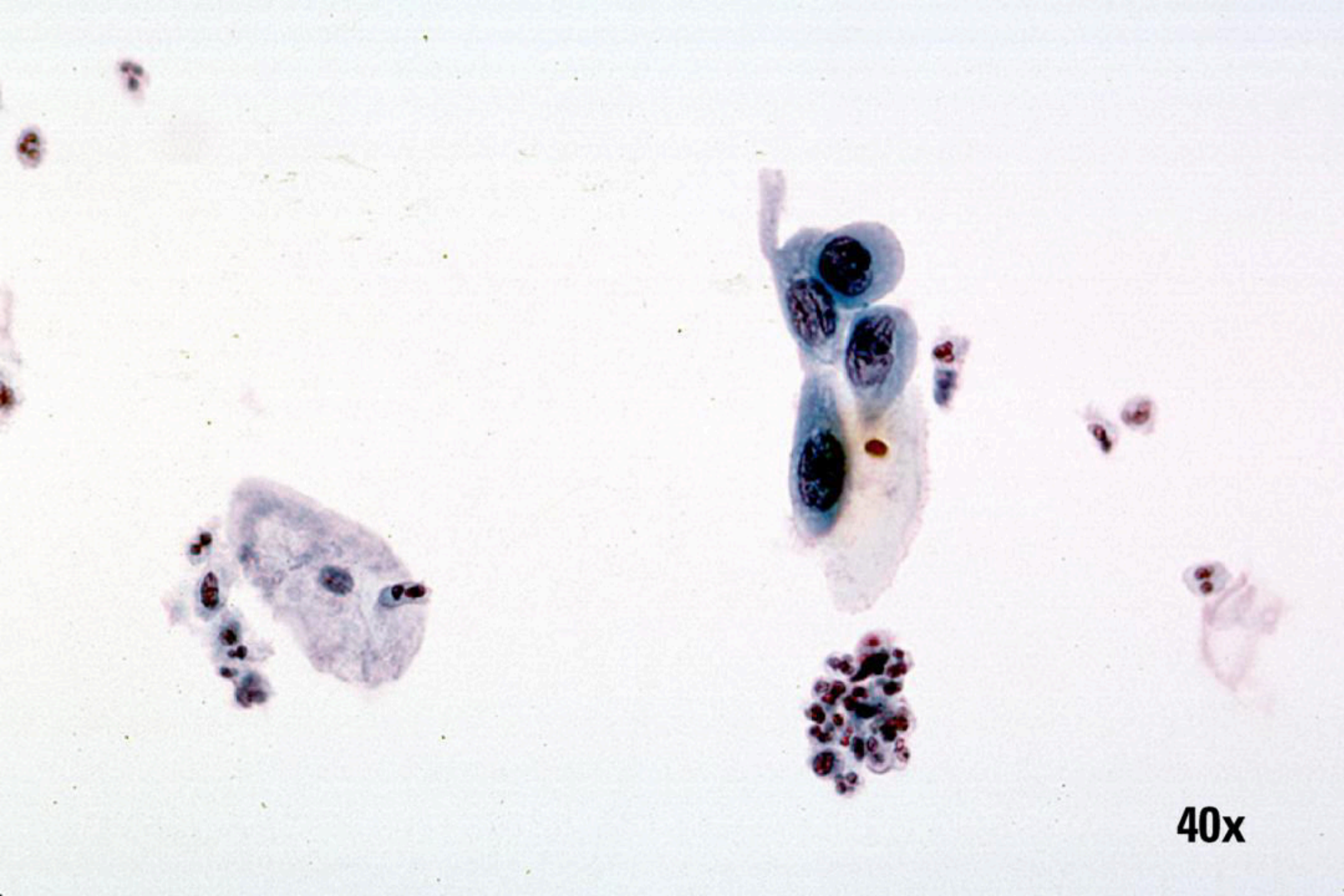
Afwijkingen in epitheelcellen - Plaveiselcellen

HSIL

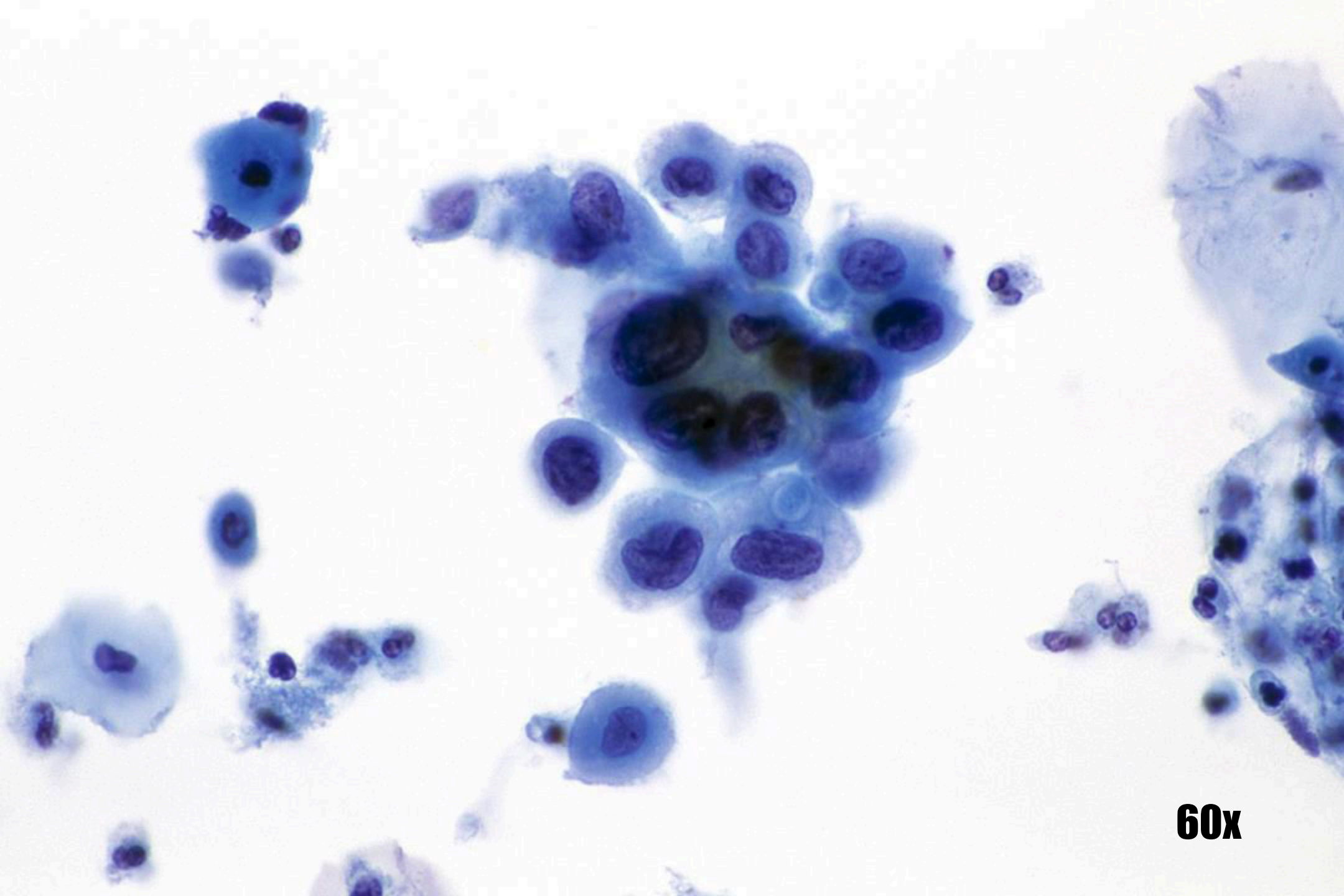
- Lagen en syncytiële groepen intact
- Cytoplasmagrenzen duidelijker
- Solitaire onrijpe cellen (met een hoge focus/diepte) in de achtergrond hebben een belangrijke signaal functie
- Onregelmatige kernmenbraan



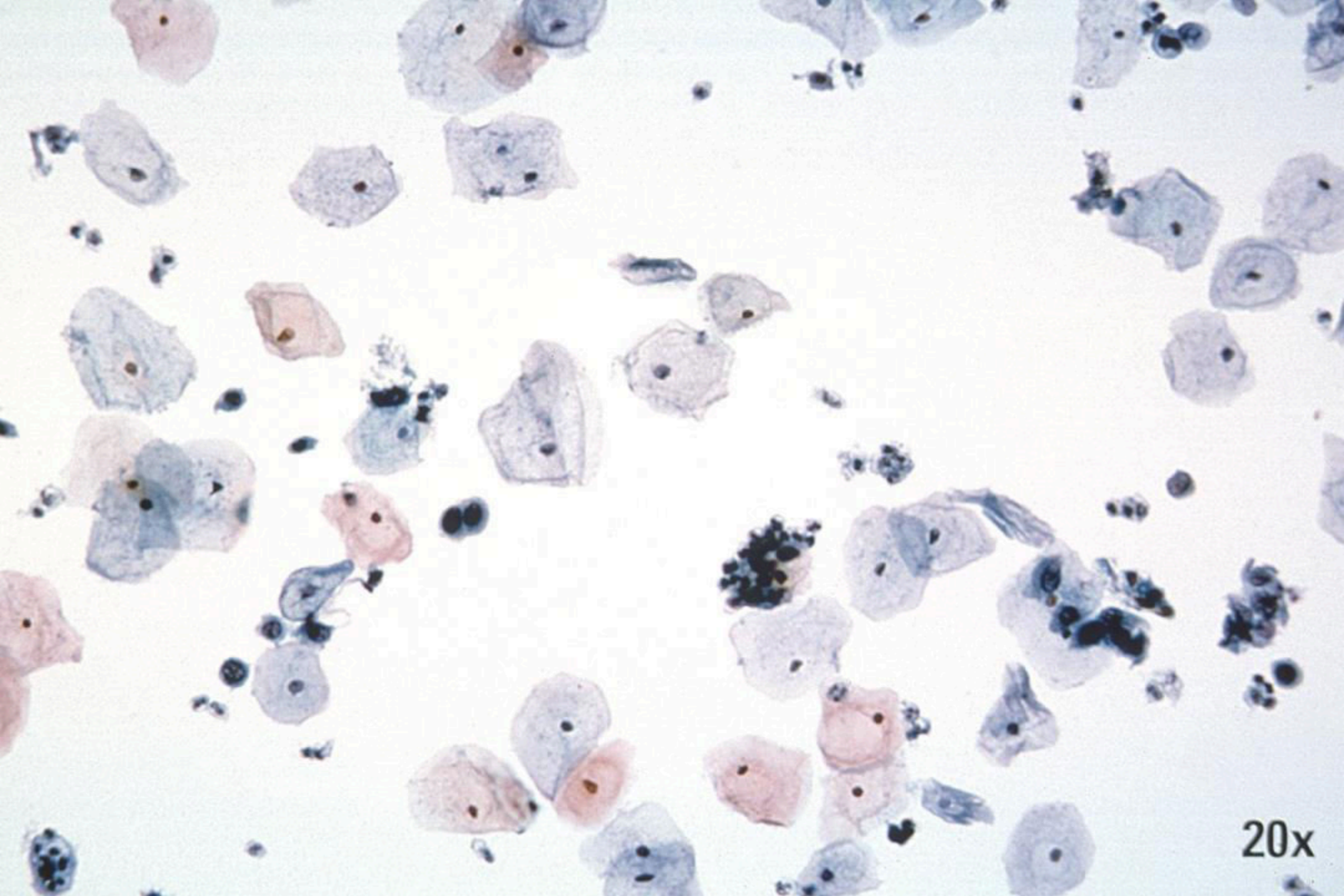
60x



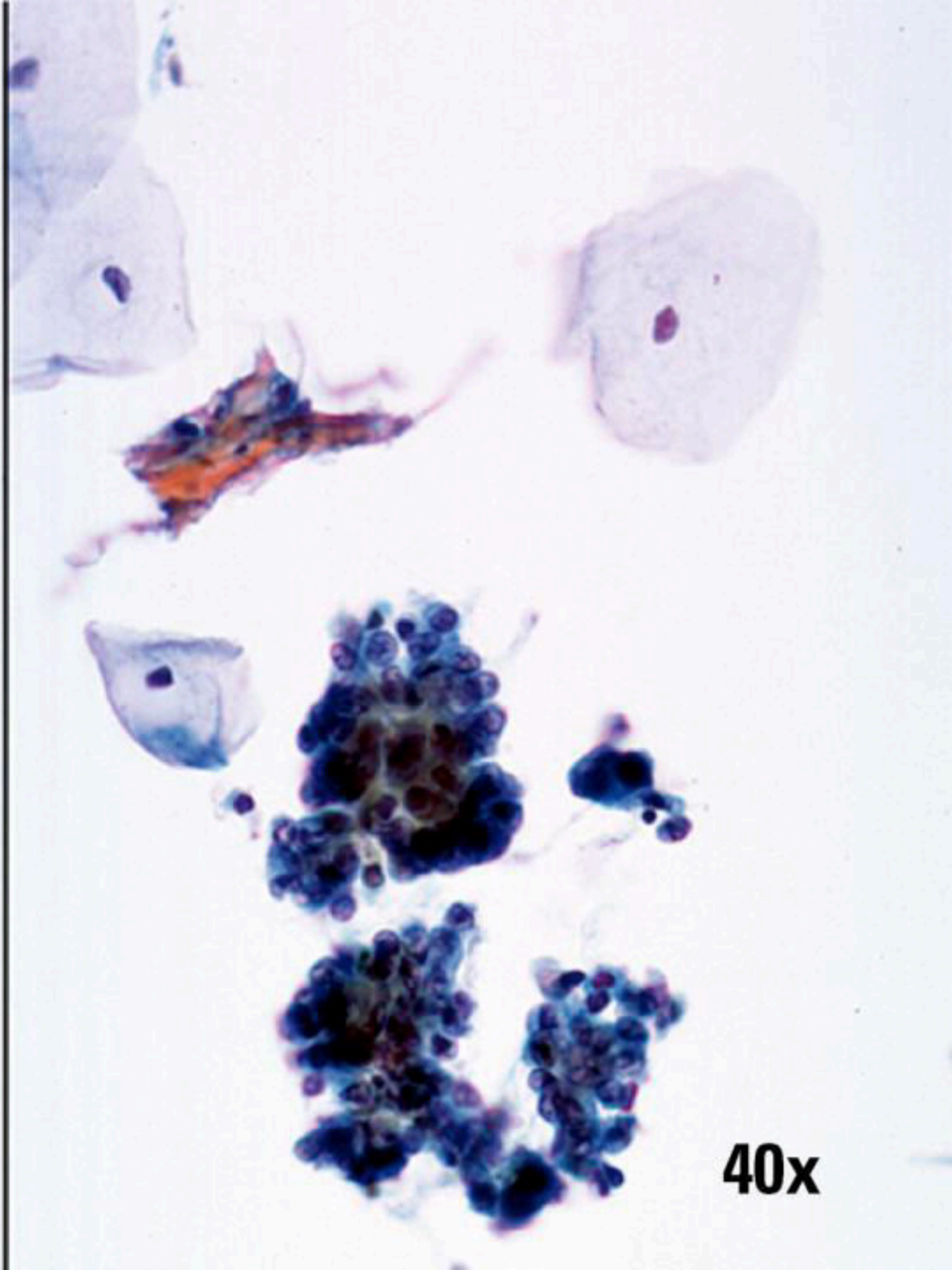
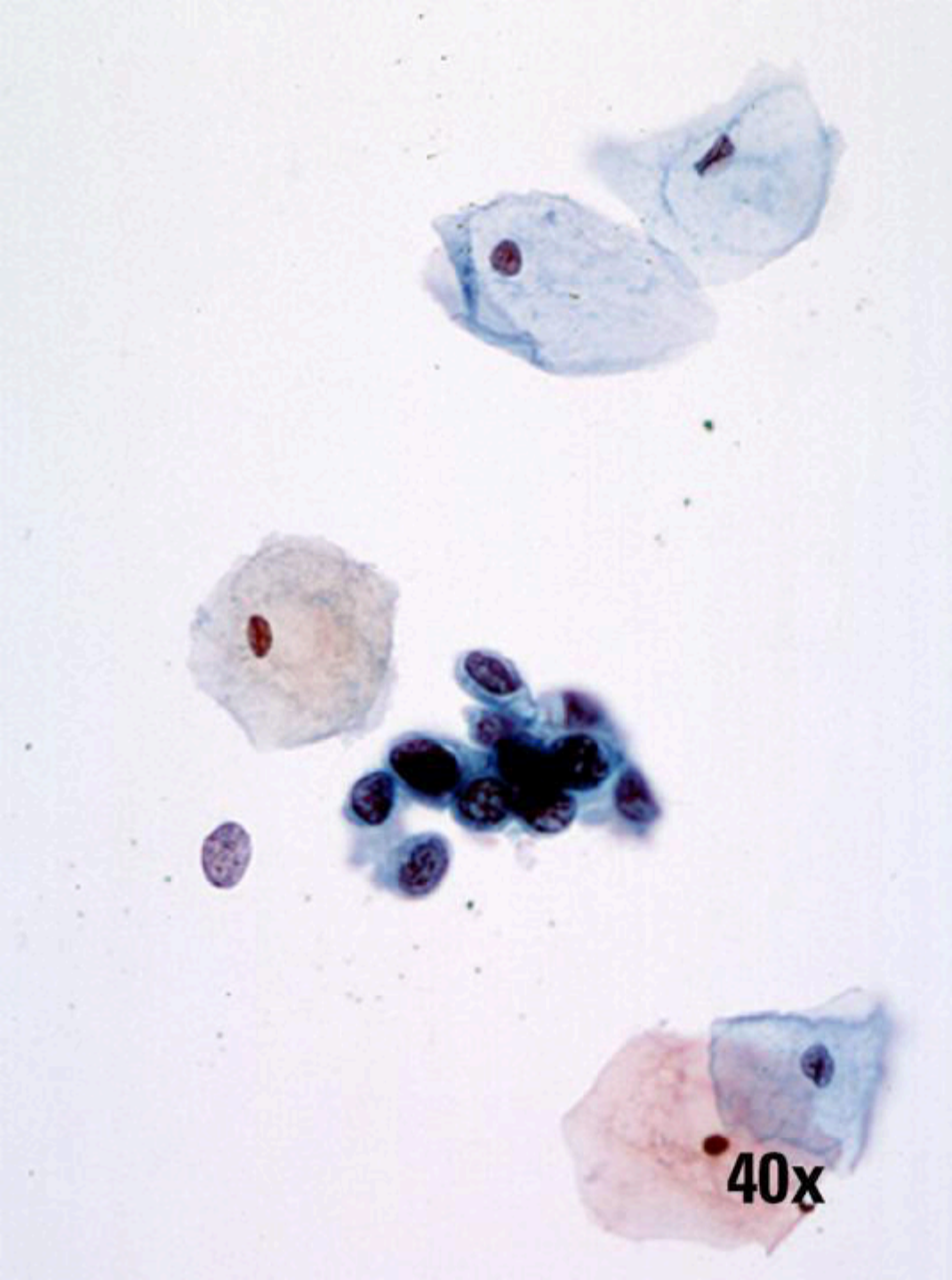
40x

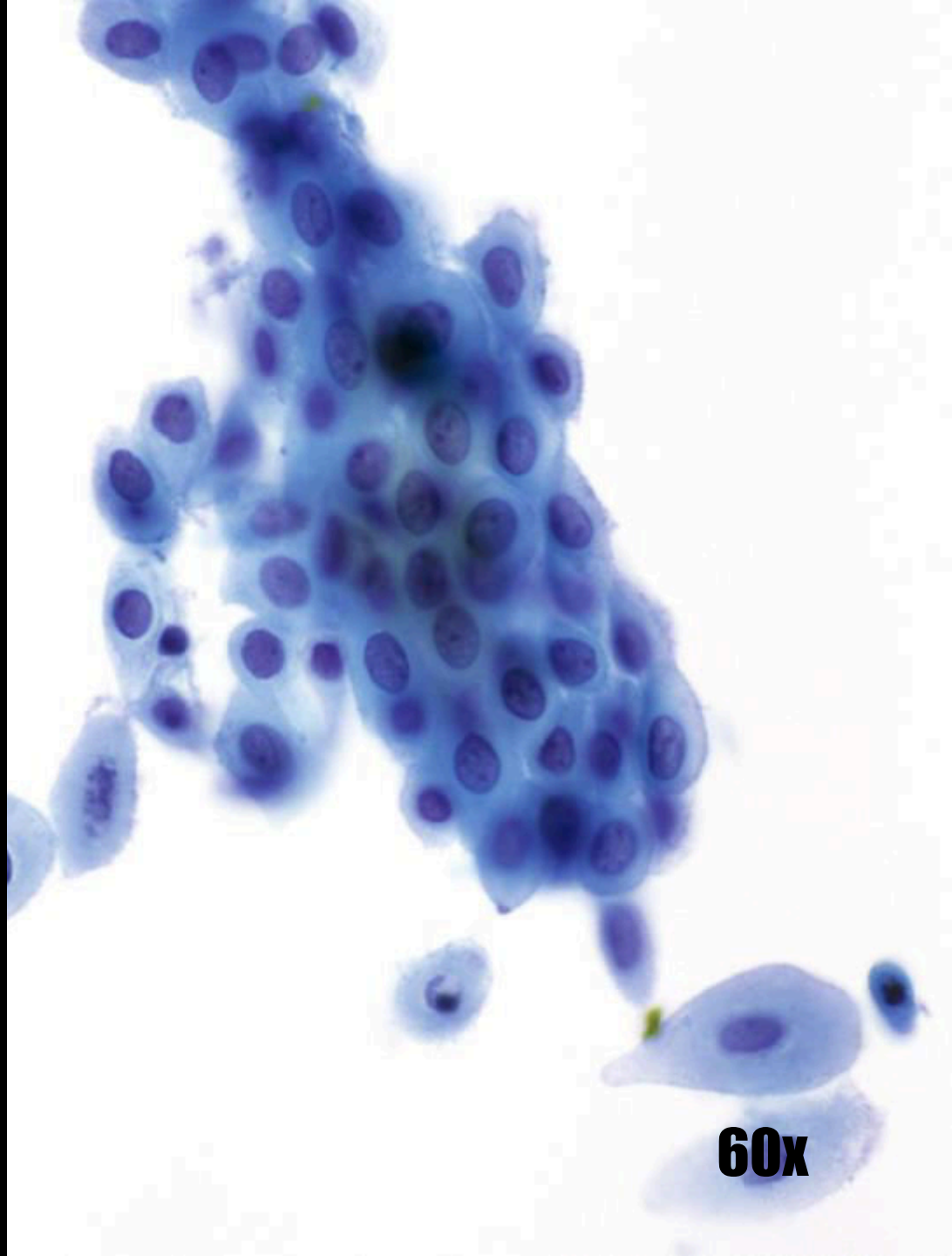
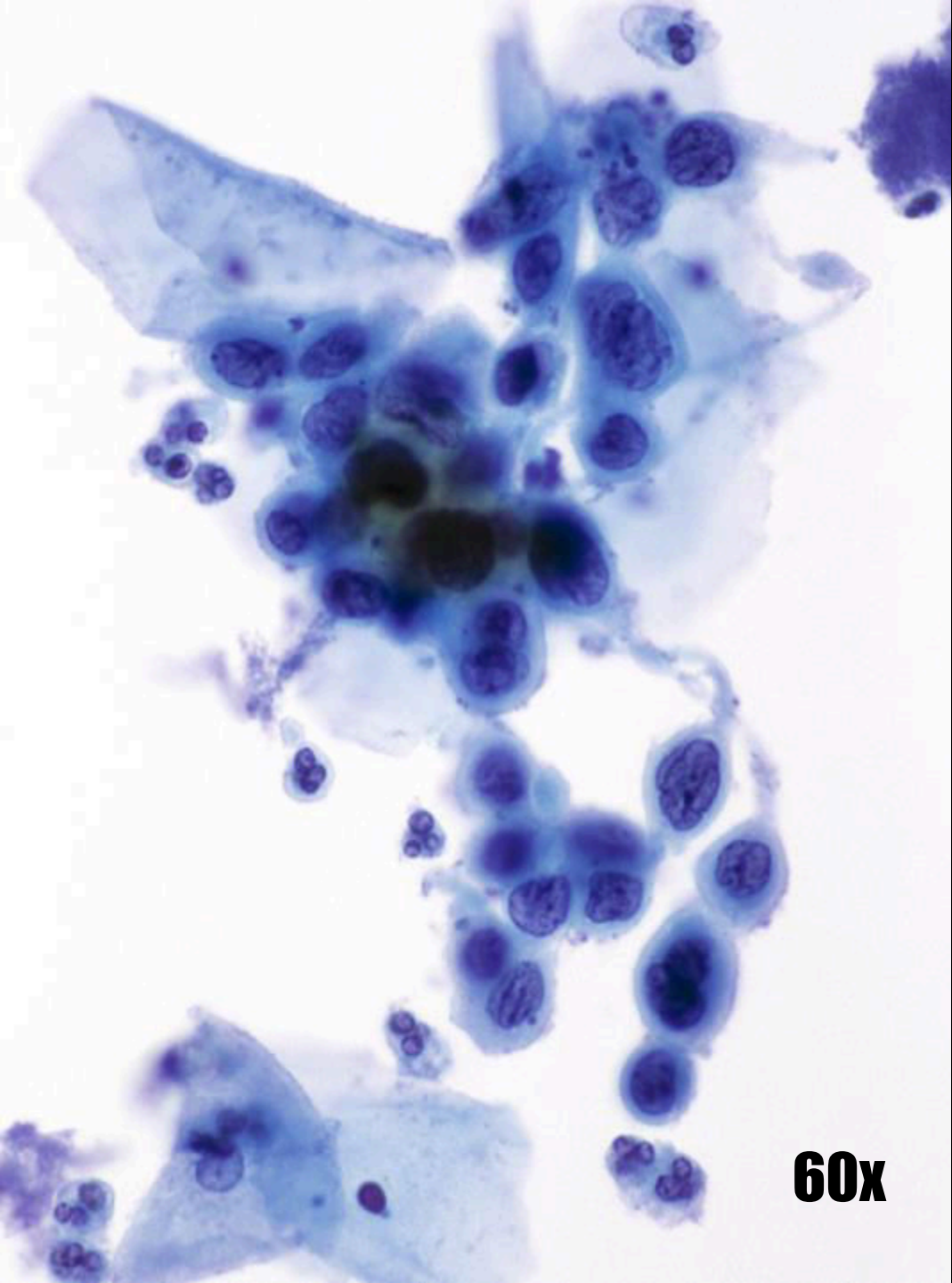


60x



20x

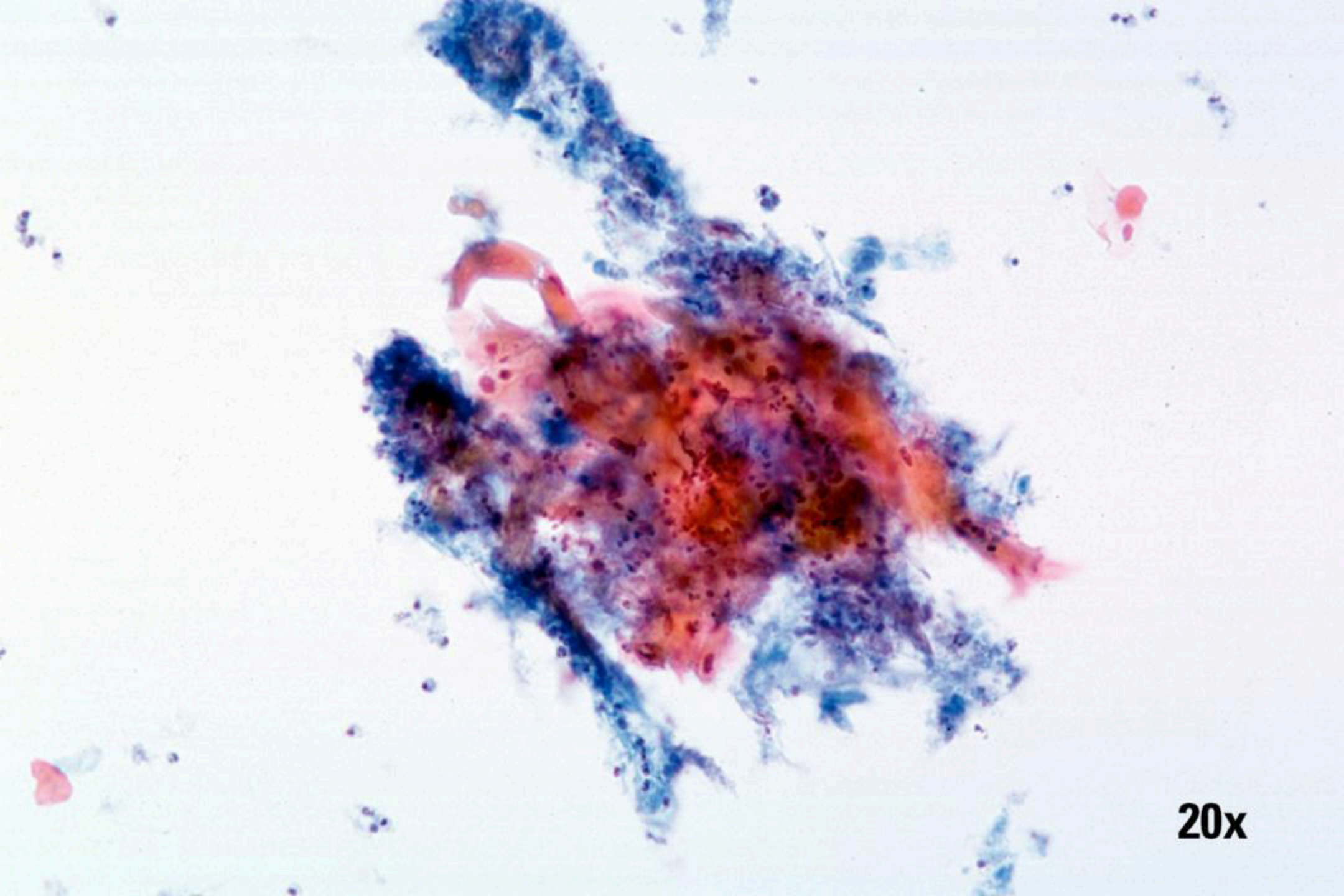




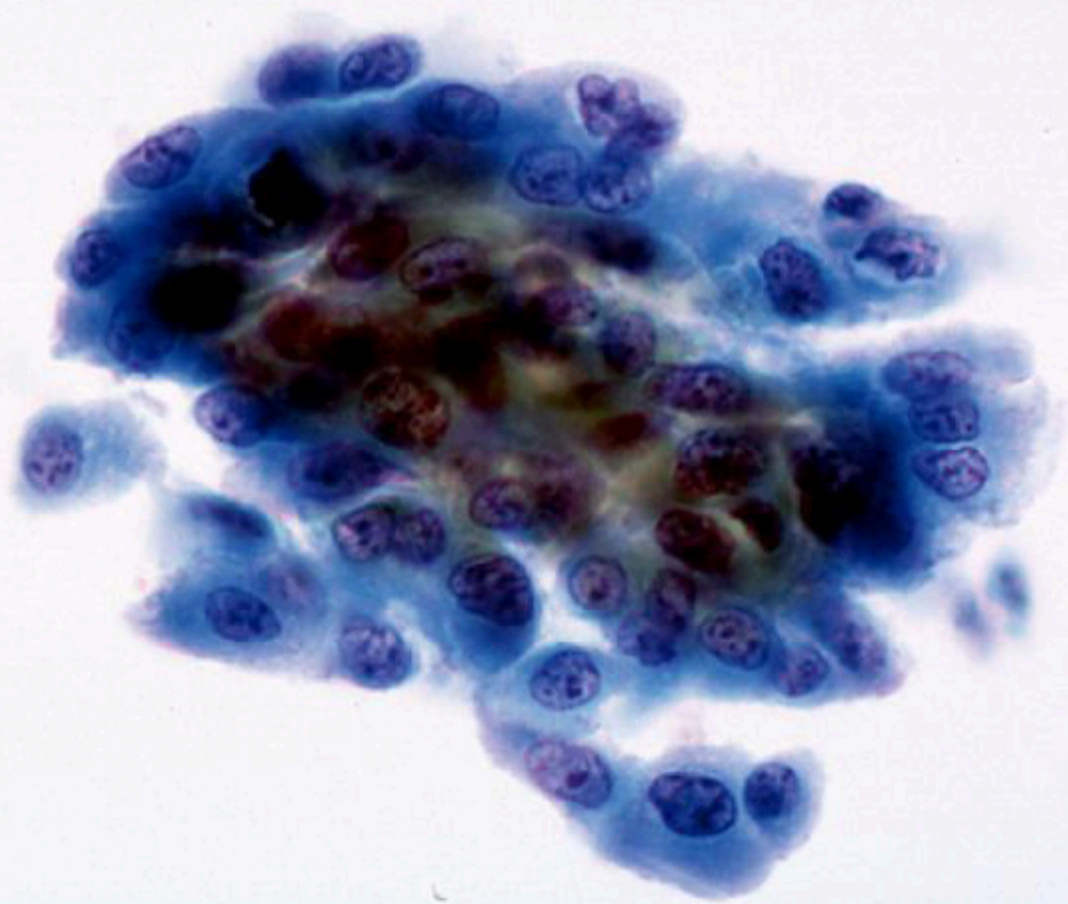
Afwijkingen in epitheelcellen - Plaveiselcellen

Plaveiselcelcarcinoom

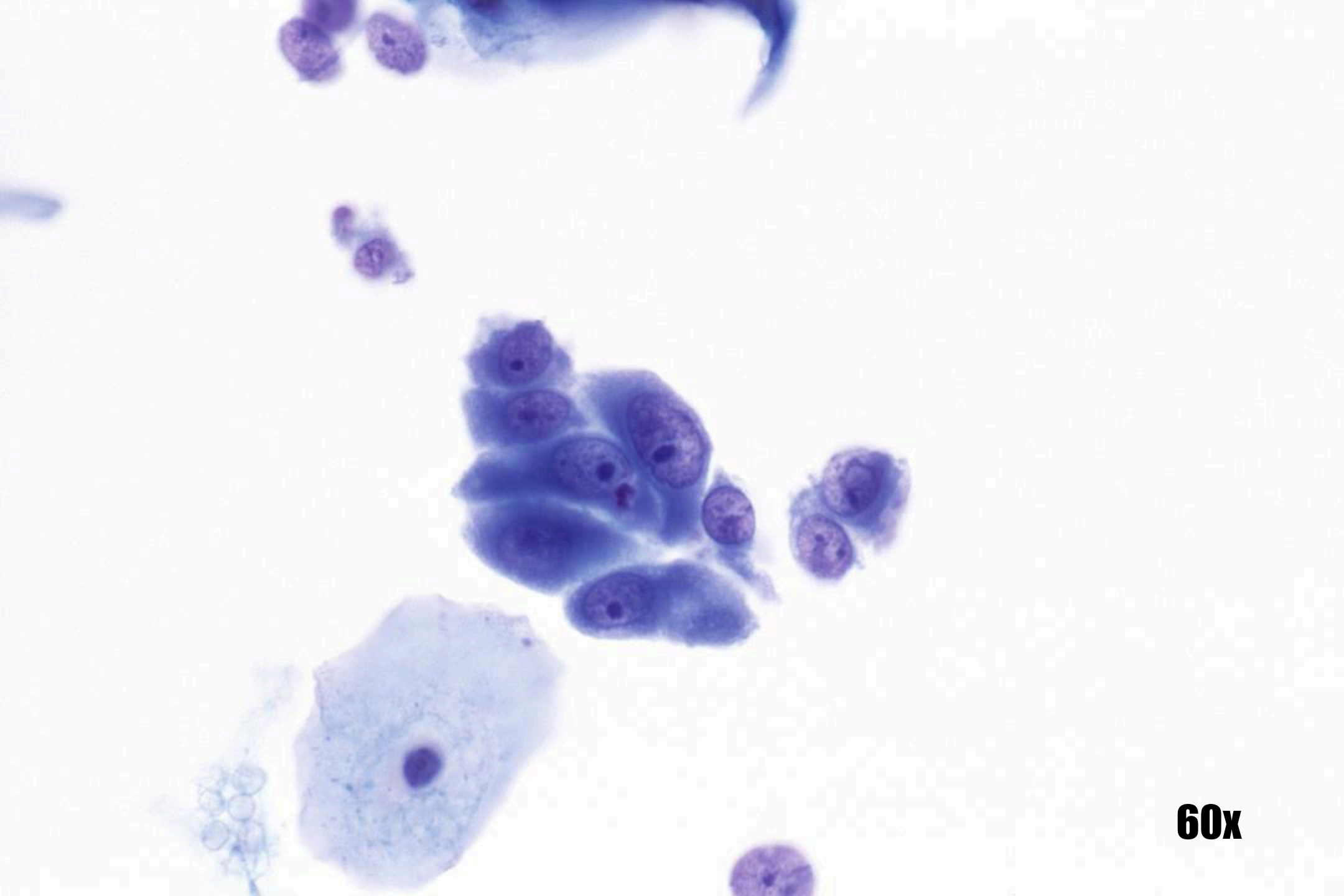
- Tumordiathese intact
- Distinctief necrotisch achtergrondpatroon
- Grotere dieptescherpte voor celgroepen
- Prominente open plekken in chromatine
- Nucleoli prominenter



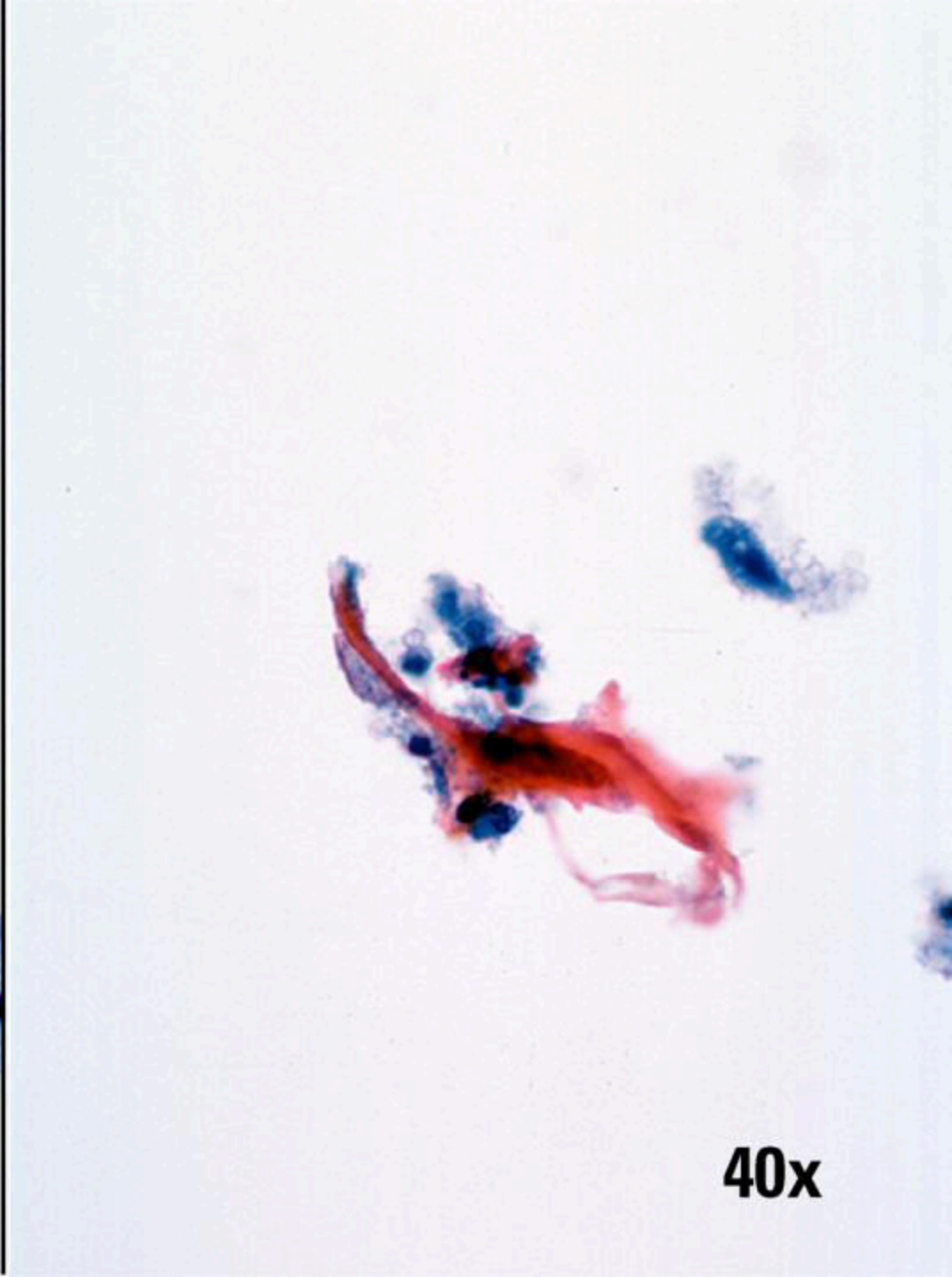
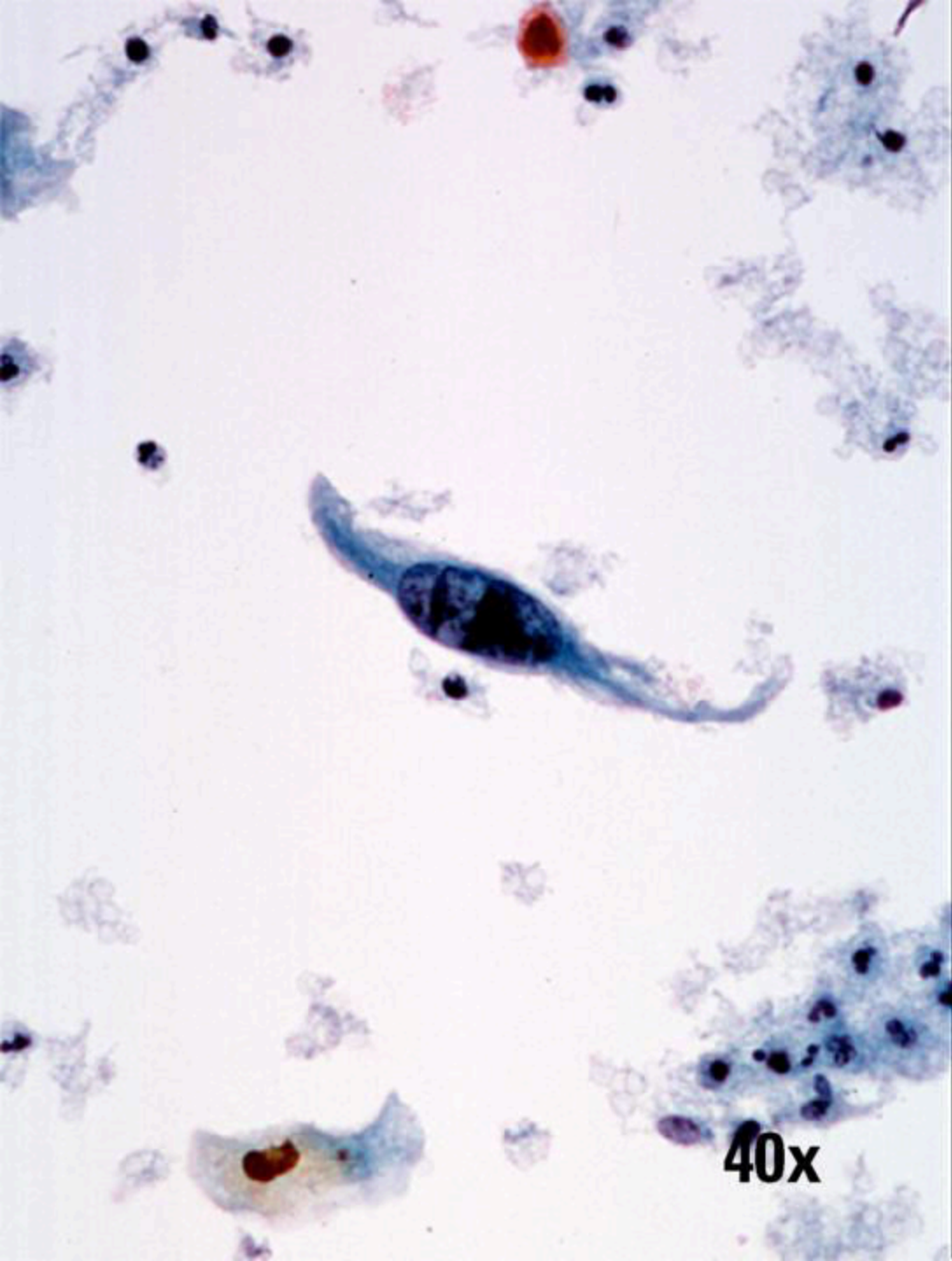
20x

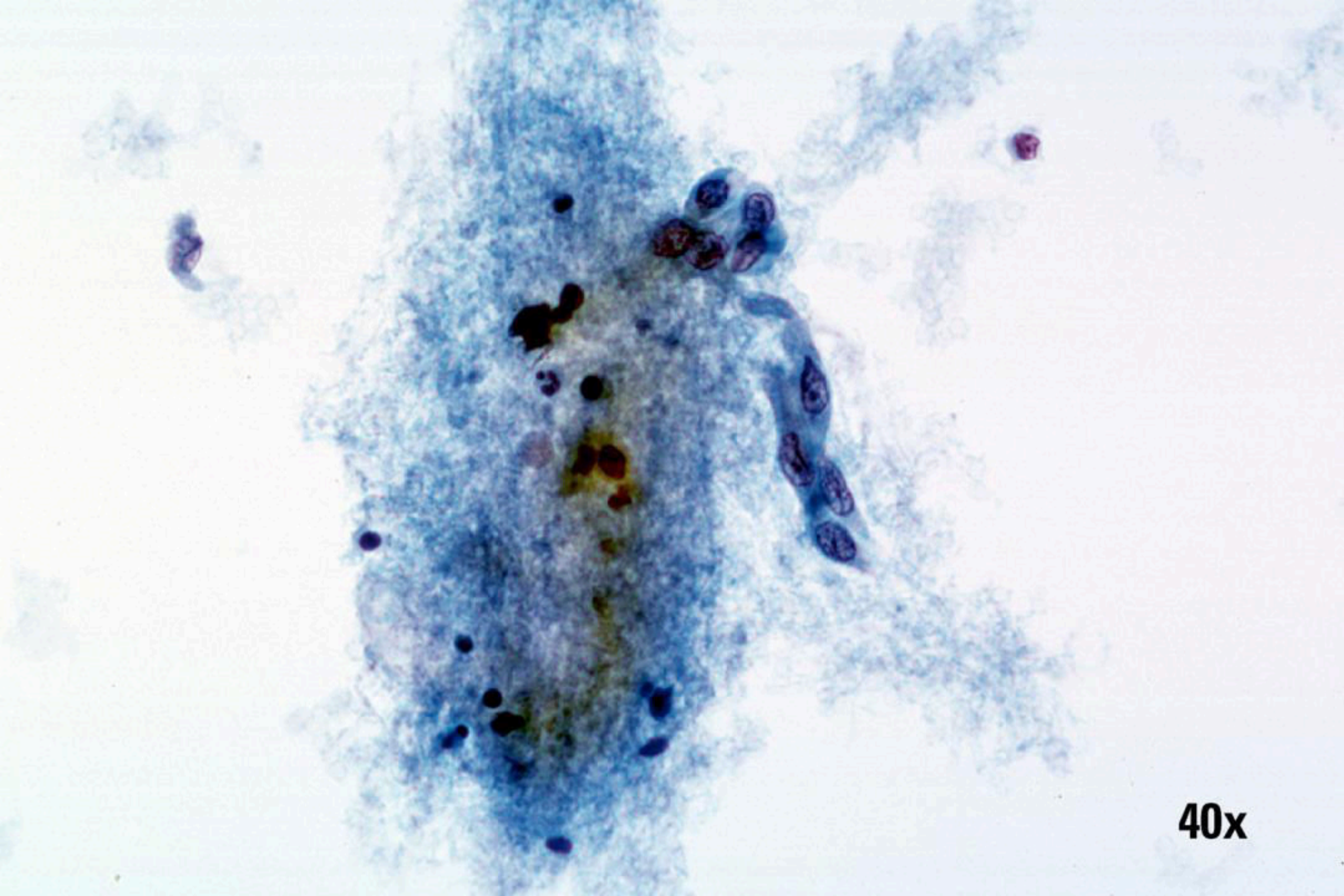


40x

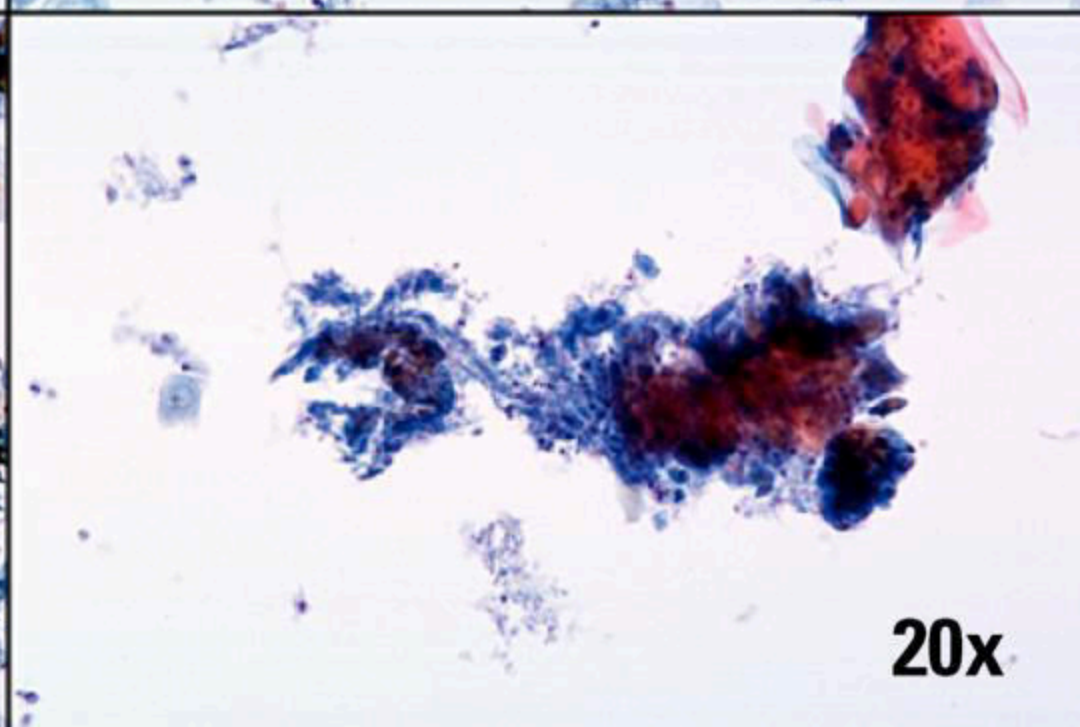
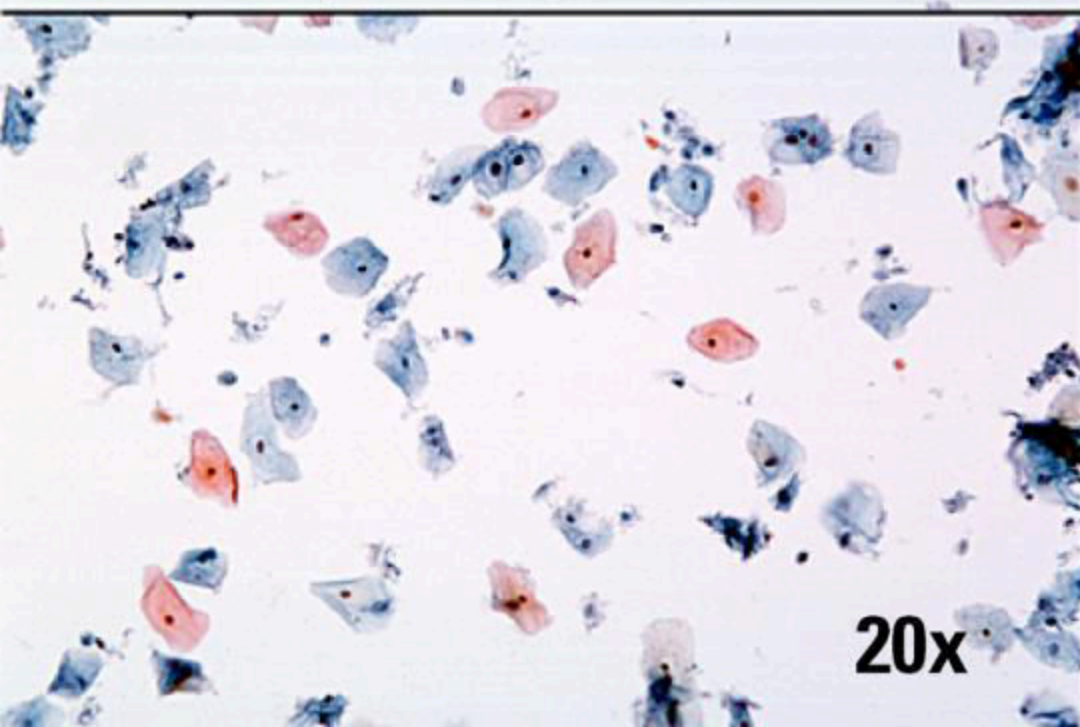
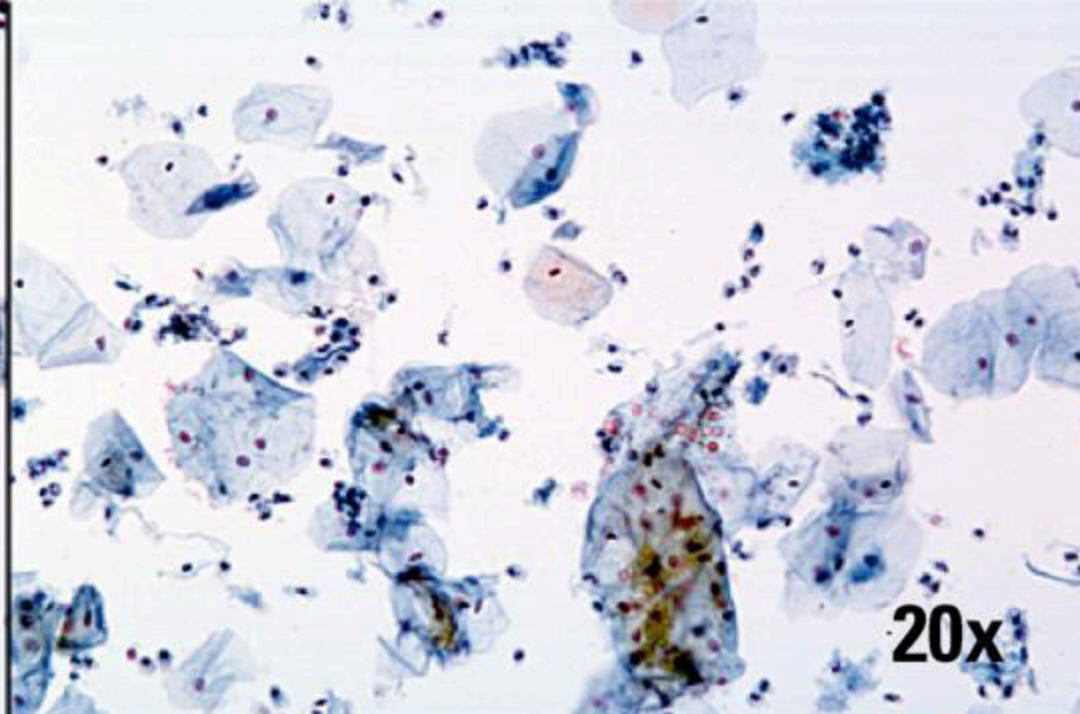
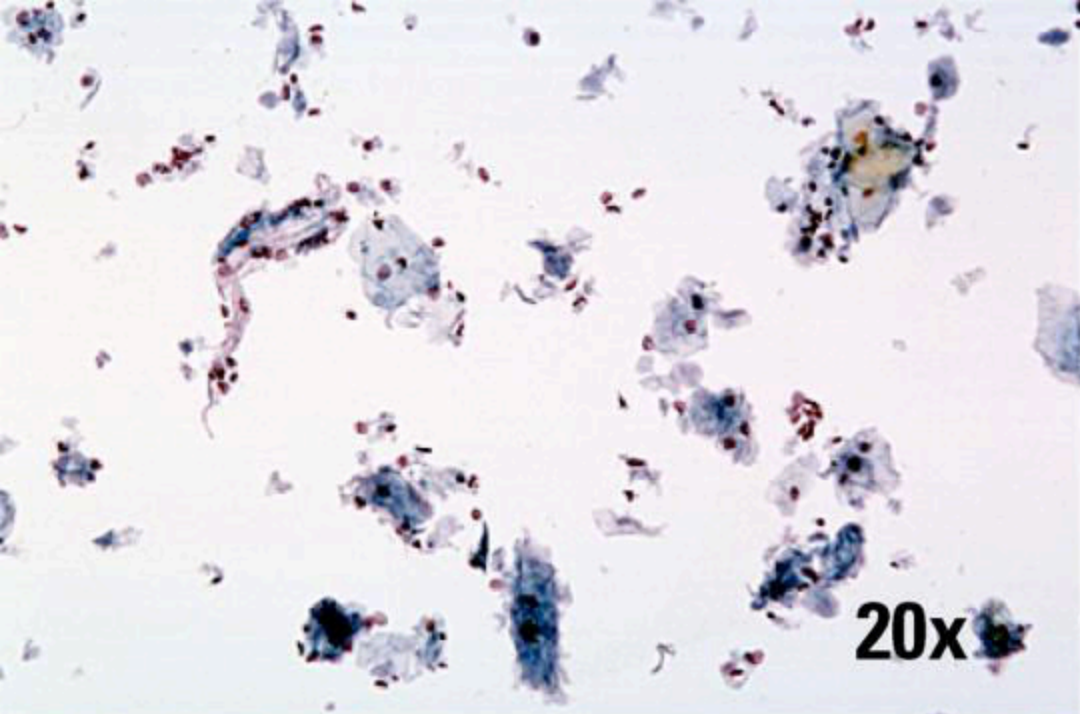


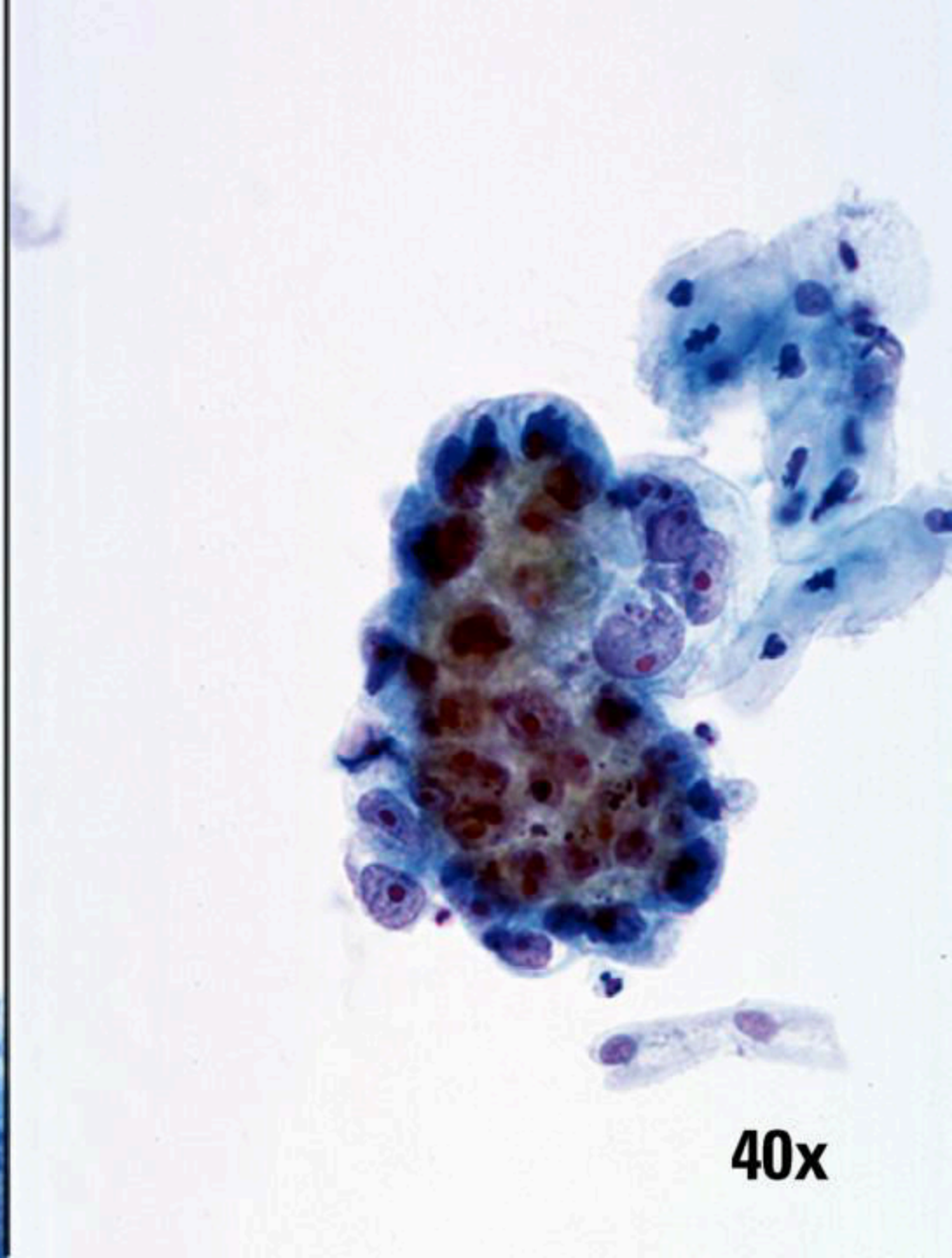
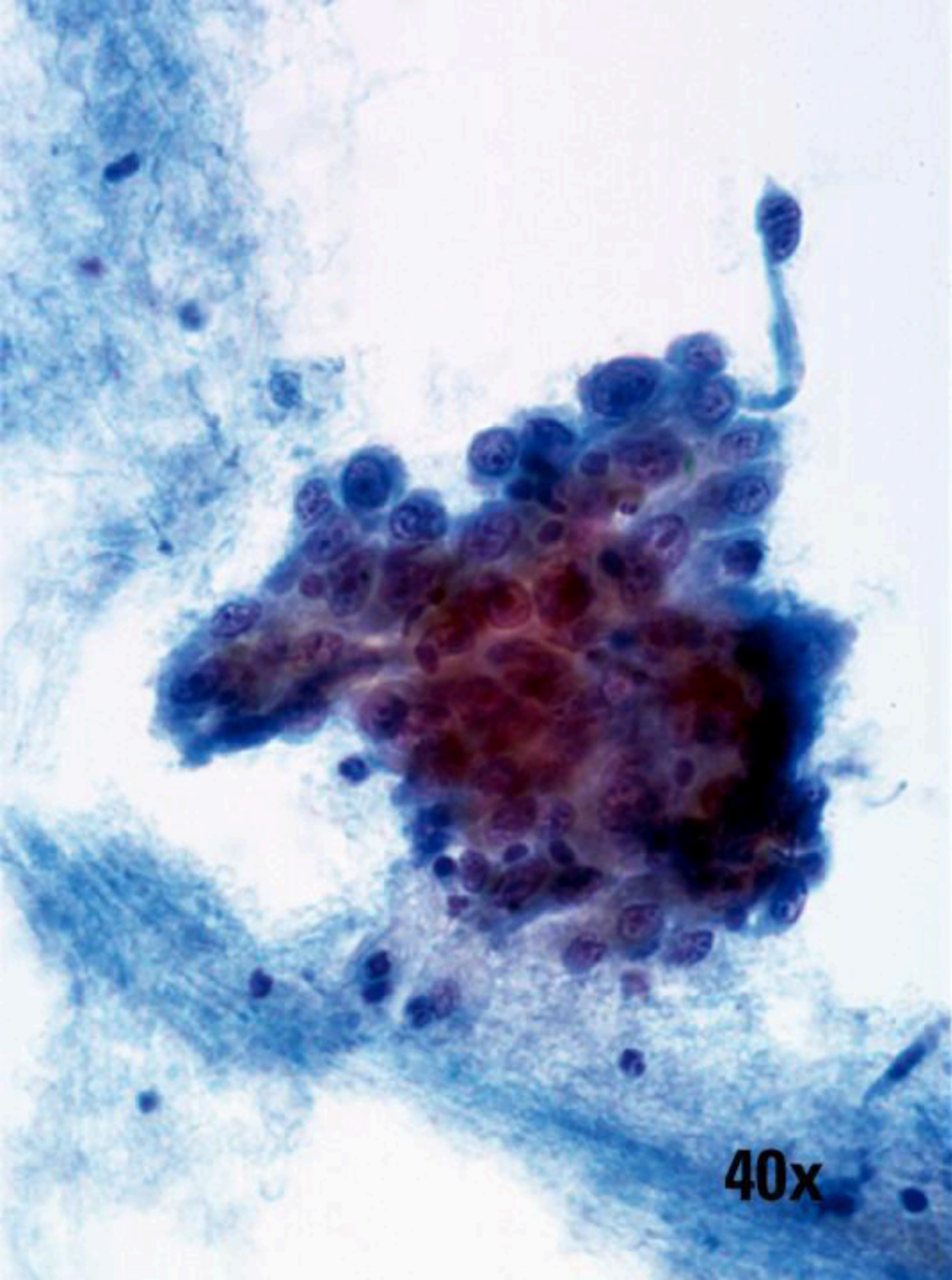
60x





40x





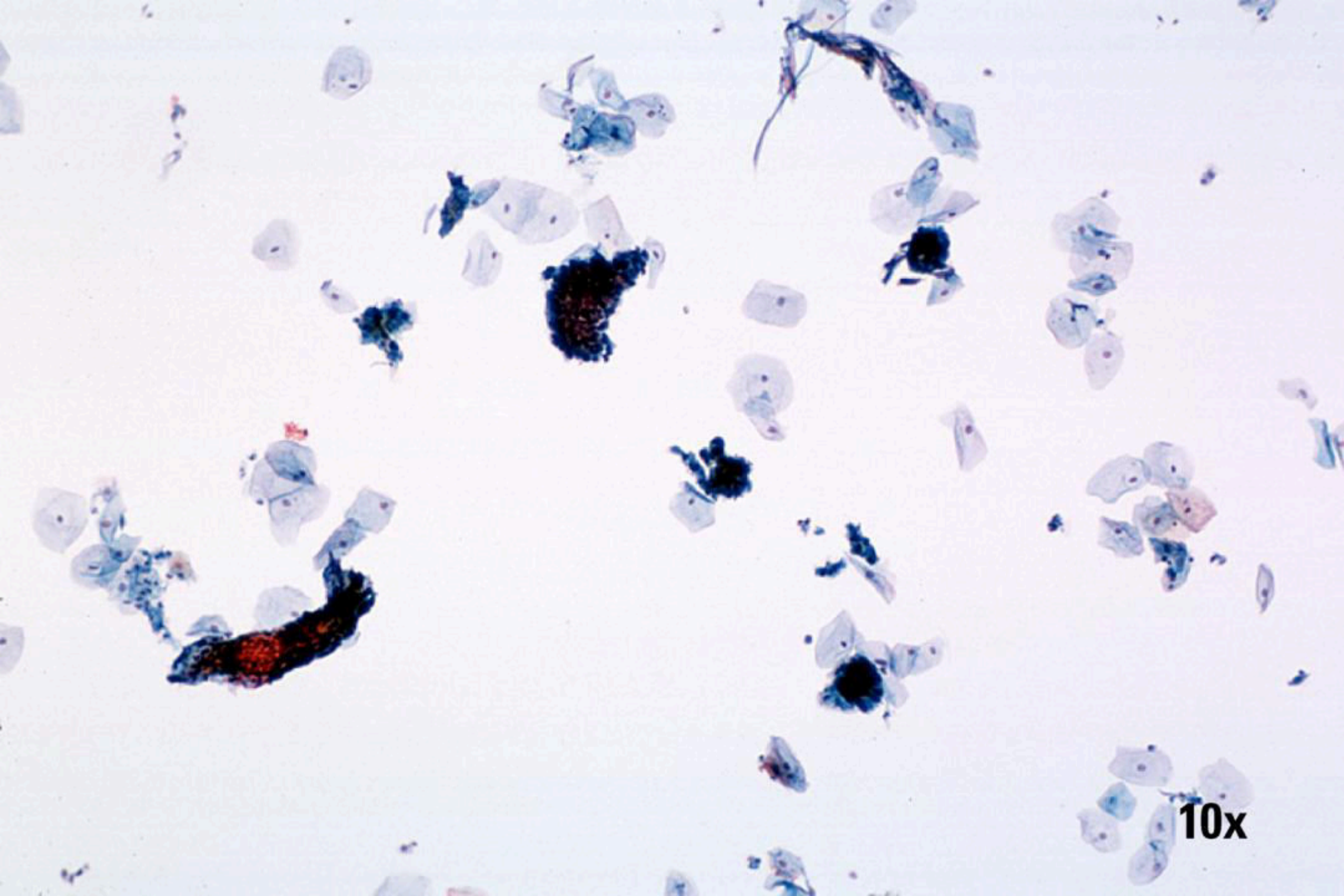
Afwijkingen in epitheelcellen – Glandulaire cellen

- Atypisch
 - Endocervicale cellen (NOS)
 - Endometriale cellen (NOS)
 - Glandulaire cellen (NOS)
- Atypisch
 - Endocervicale cellen, pleit voor neoplastisch
 - Glandulaire cellen, pleit voor neoplastisch
- Endocervicaal adenocarcinoom in situ

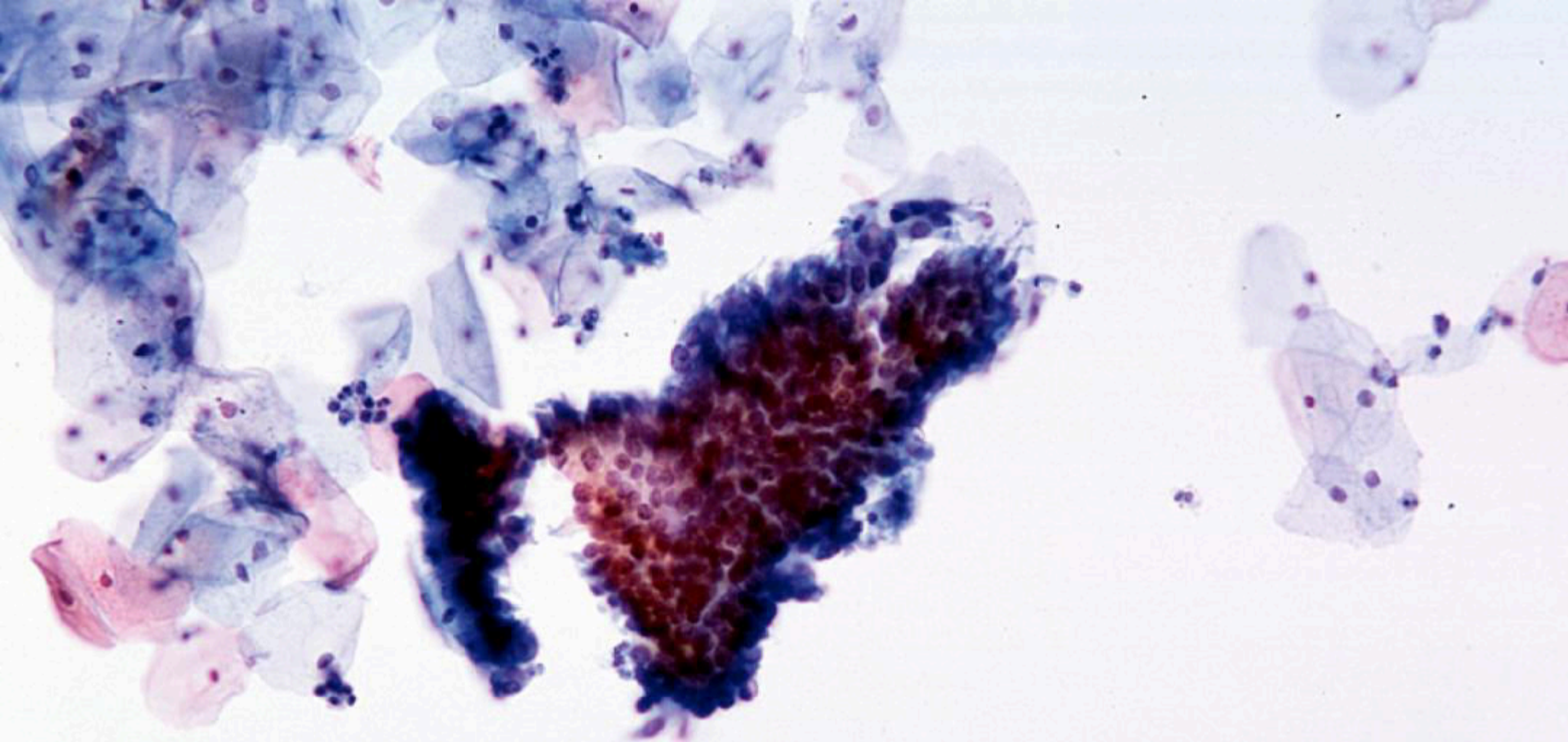
Afwijkingen in epitheelcellen - Glandulair

Endocervicaal adenocarcinoom in situ (AIS)

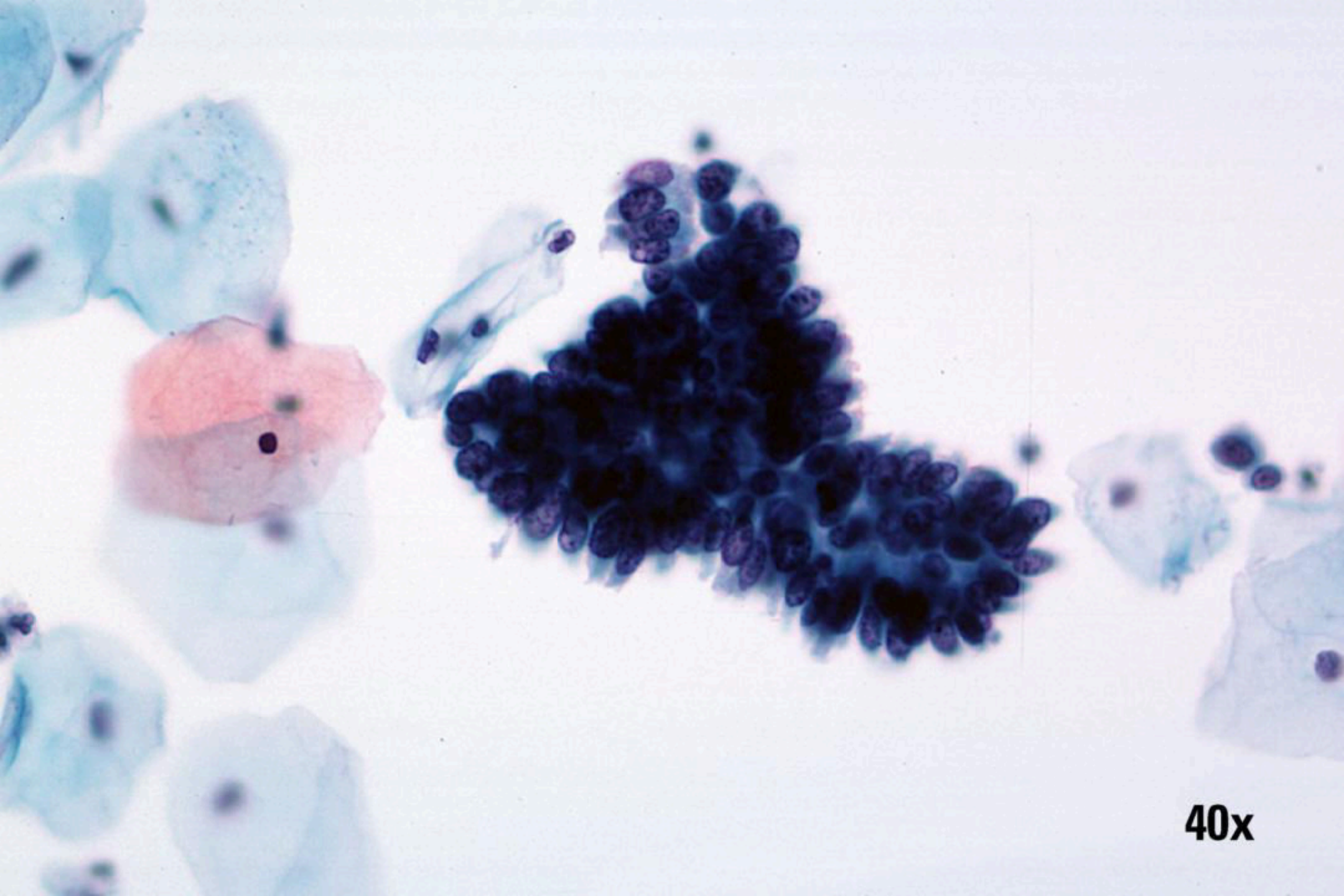
- Abnormale structuurpatronen intact
- Nuclear crowding met hyperchromasie
- Pseudostratificatie, „feathering“
geïdentificeerd
- Rozetten en strips
- Vaak zijn nucleoli aanwezig



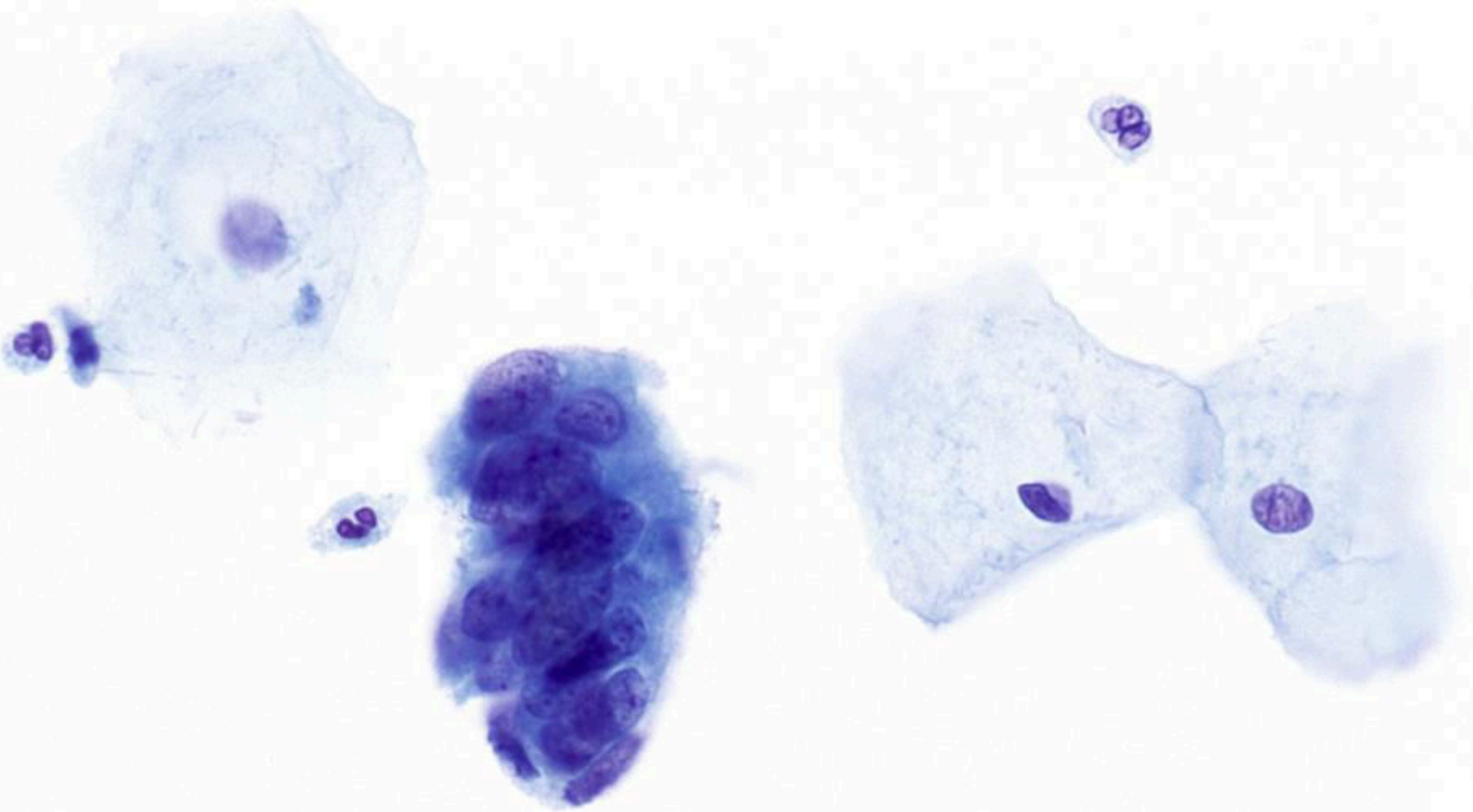
10x



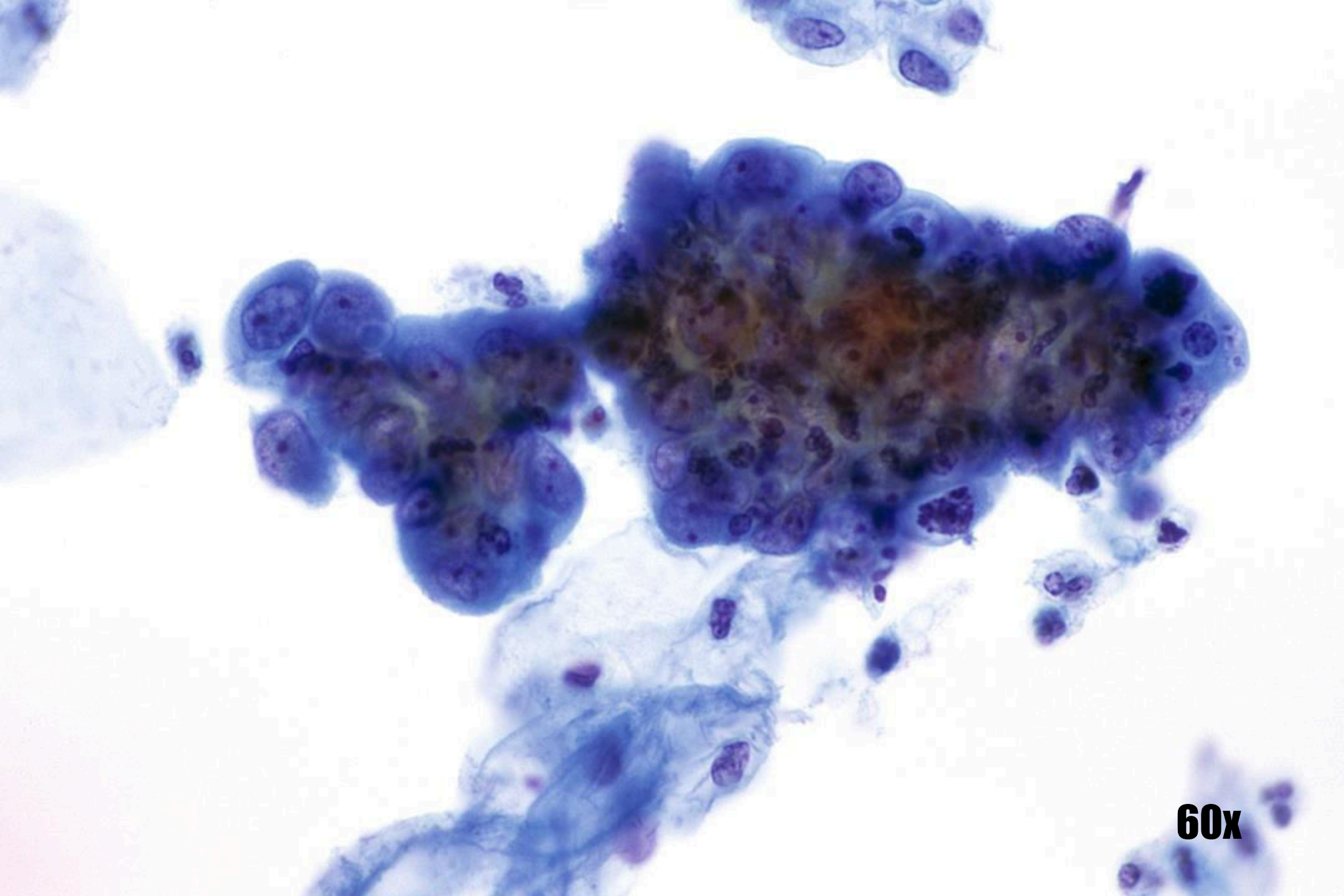
20x



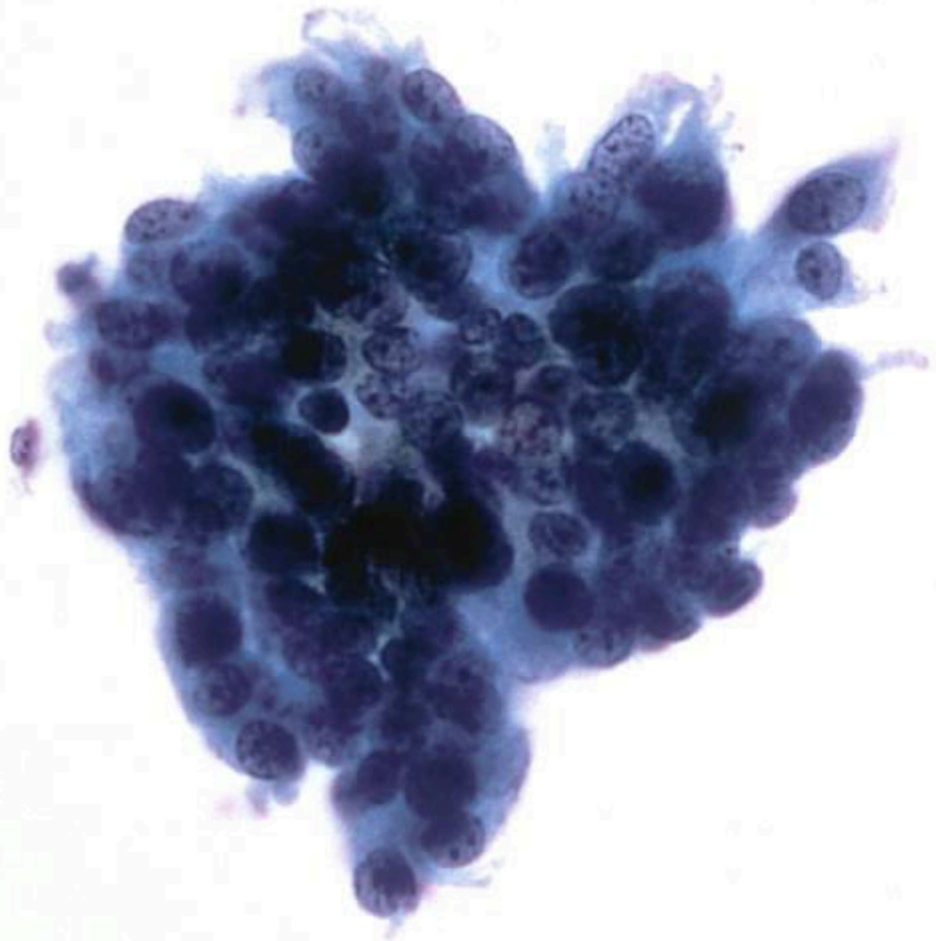
40x



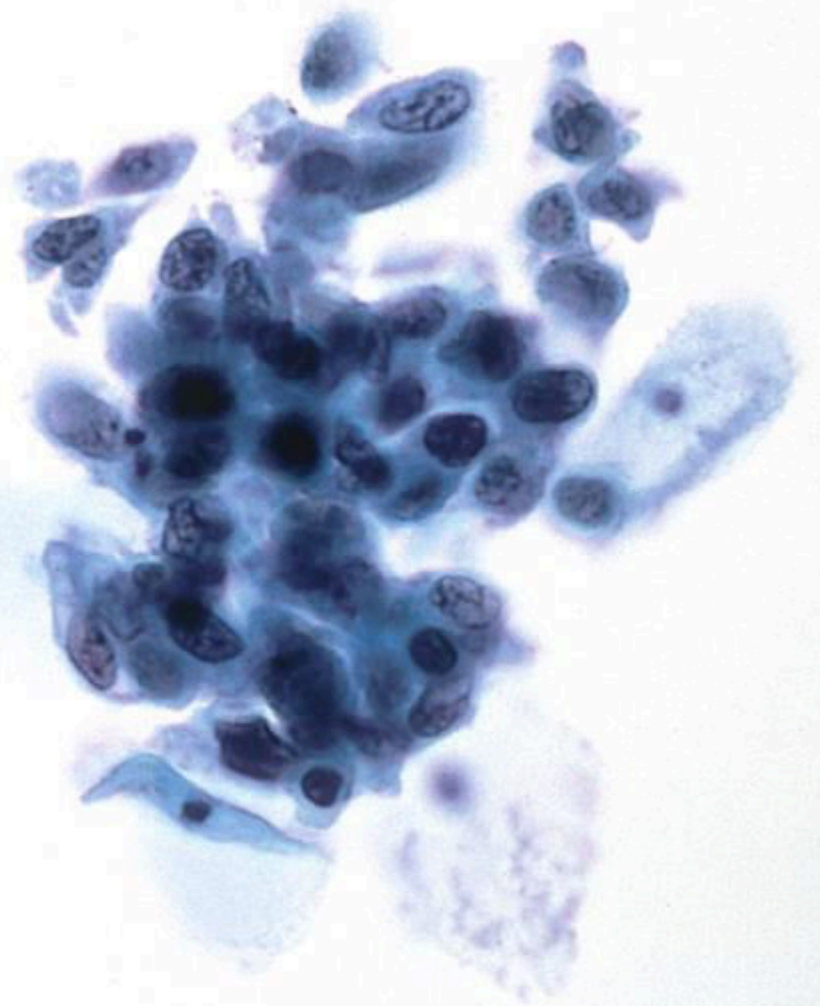
40x



60x



40x

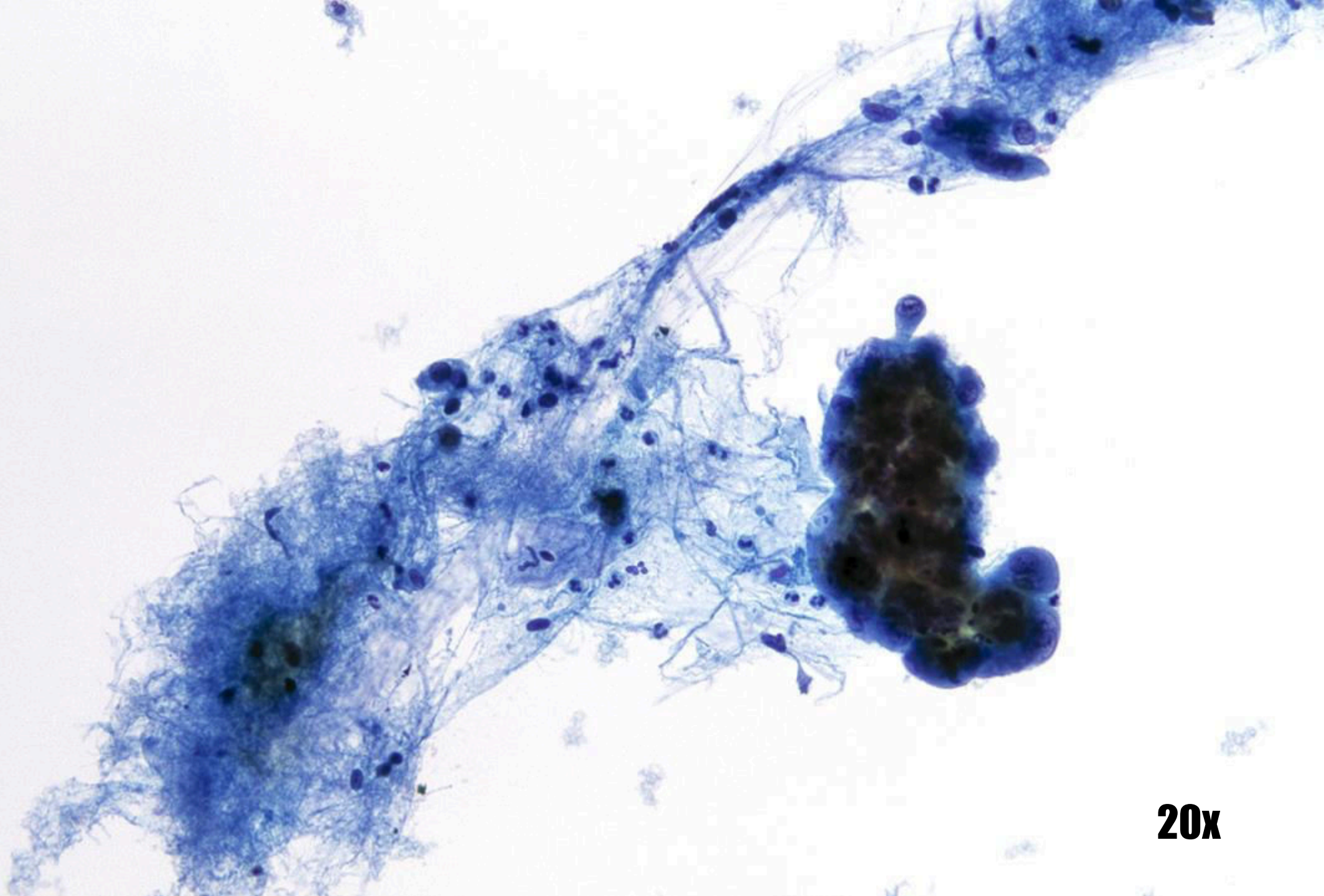


40x

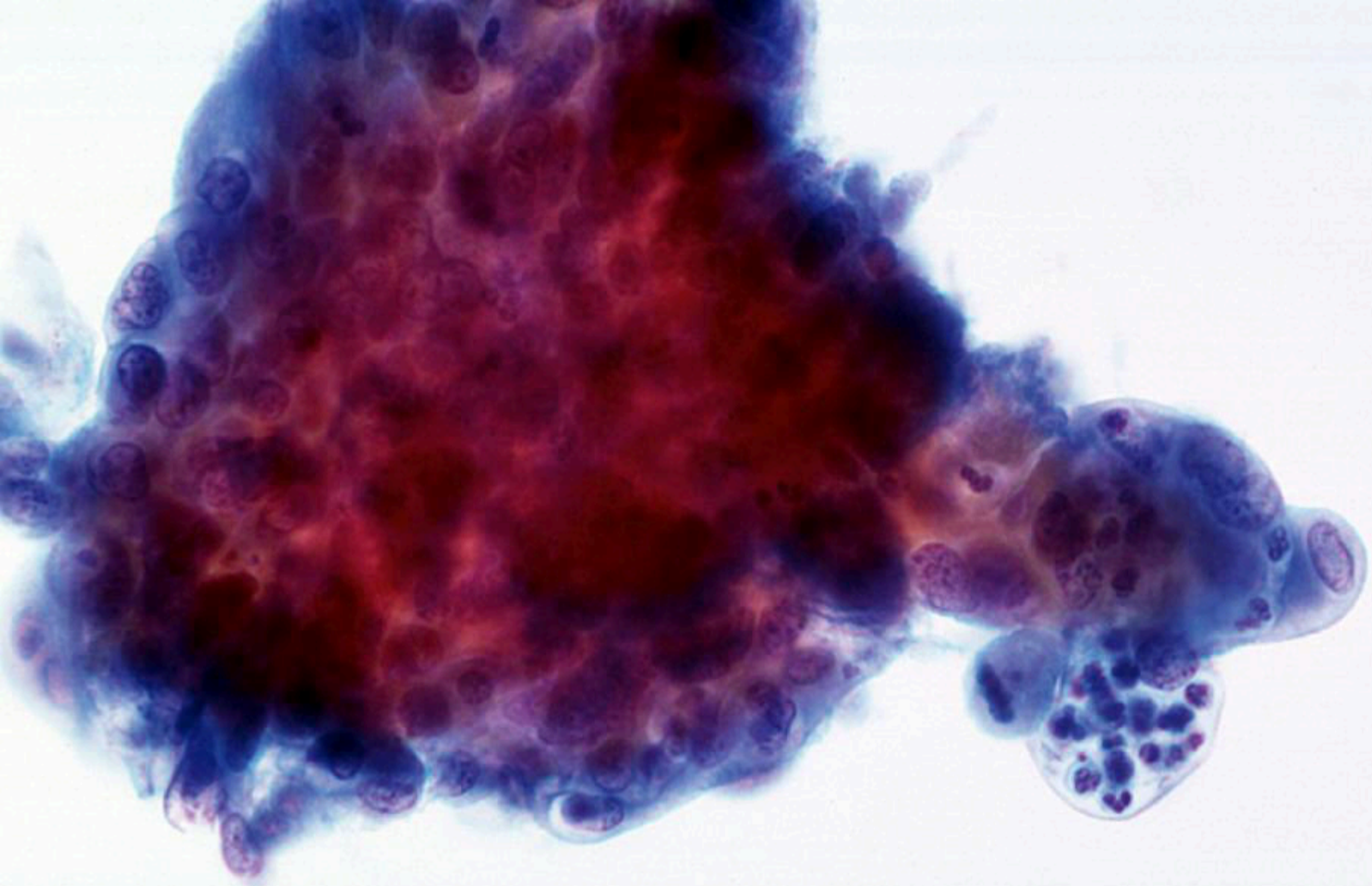
Afwijkingen in epitheelcellen - Glandulair

Adenocarcinoom

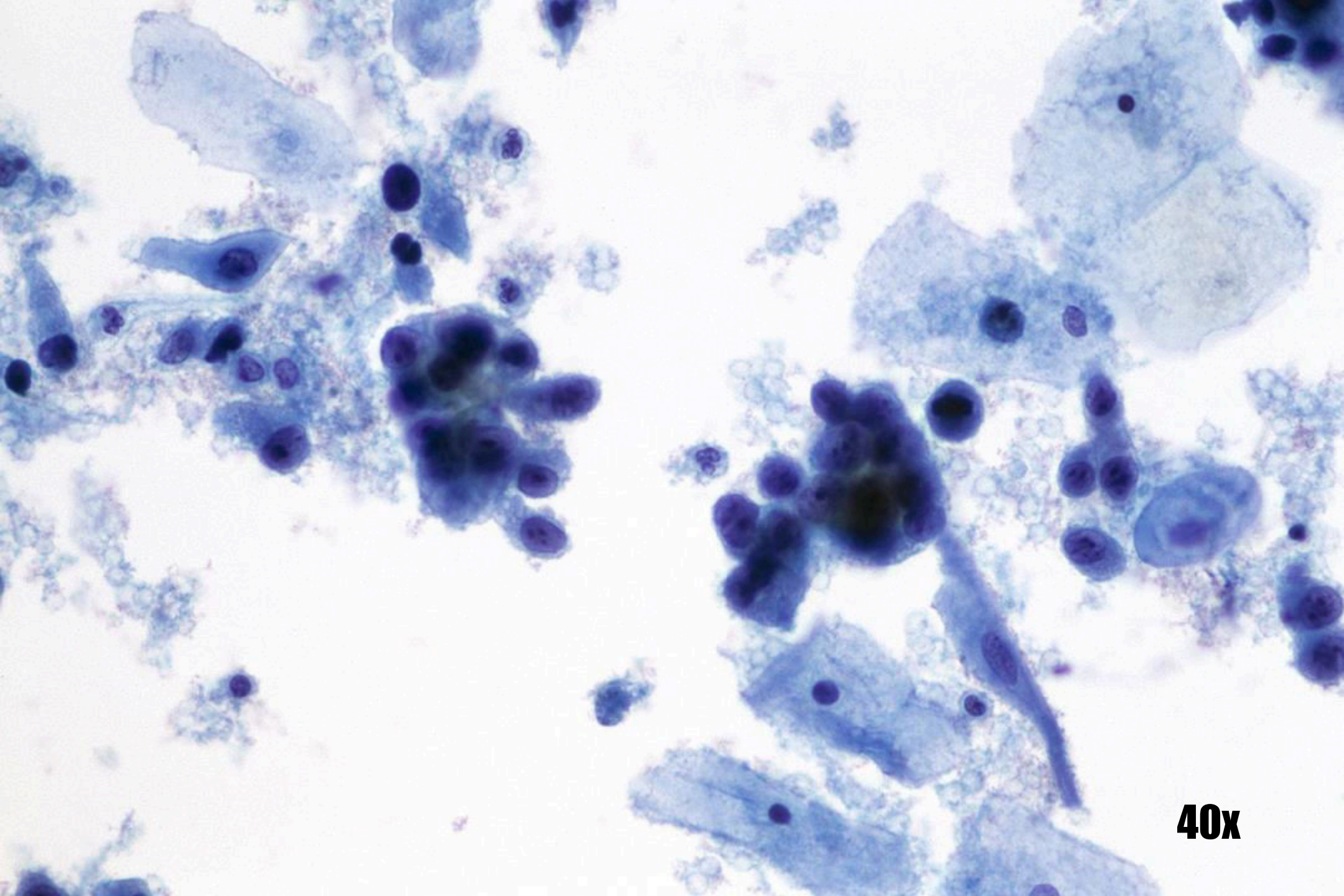
- 3D-celclusters intact
- Goed geconserveerde kernkenmerken
- Tumordiathese kan waargenomen worden



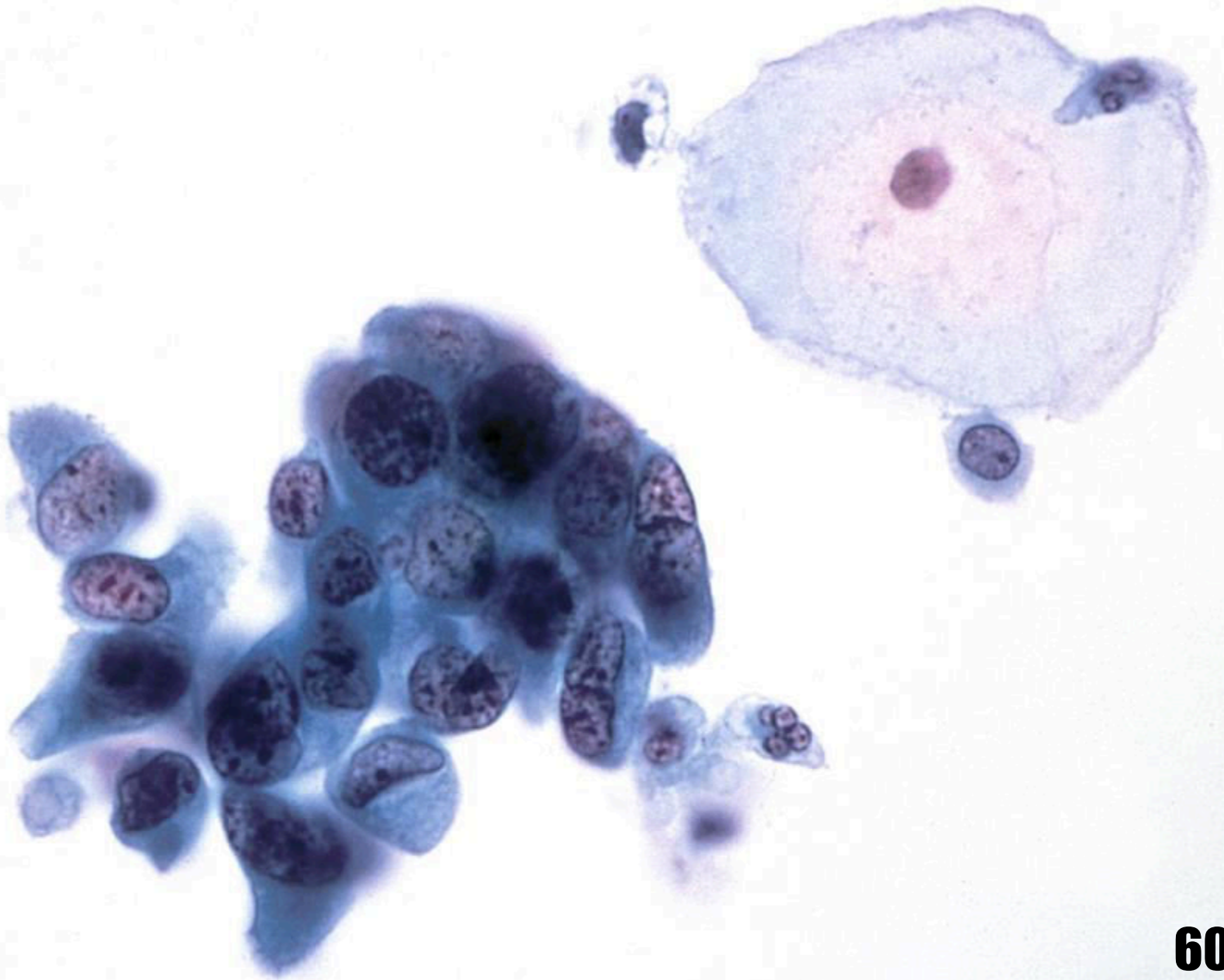
20x



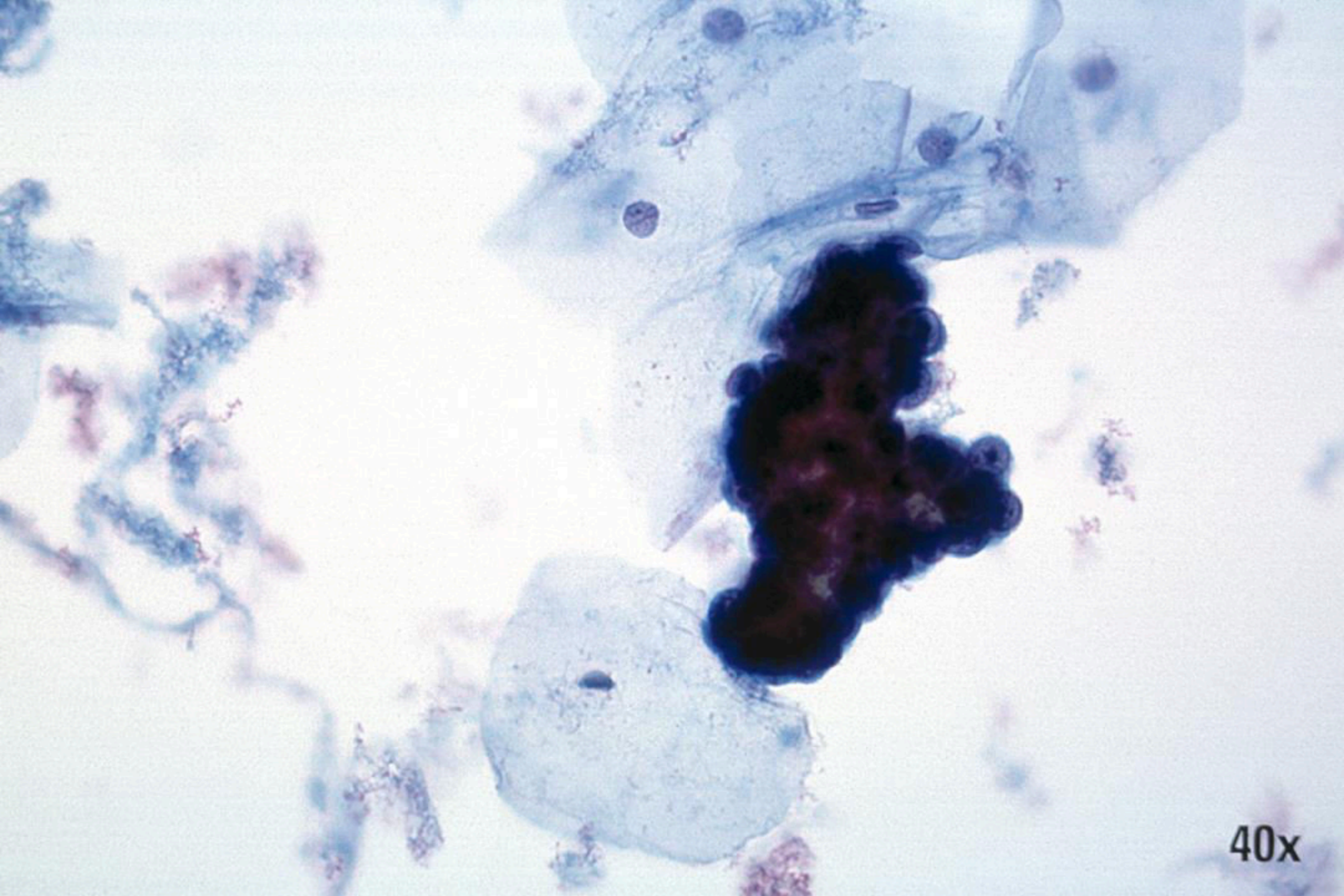
40x



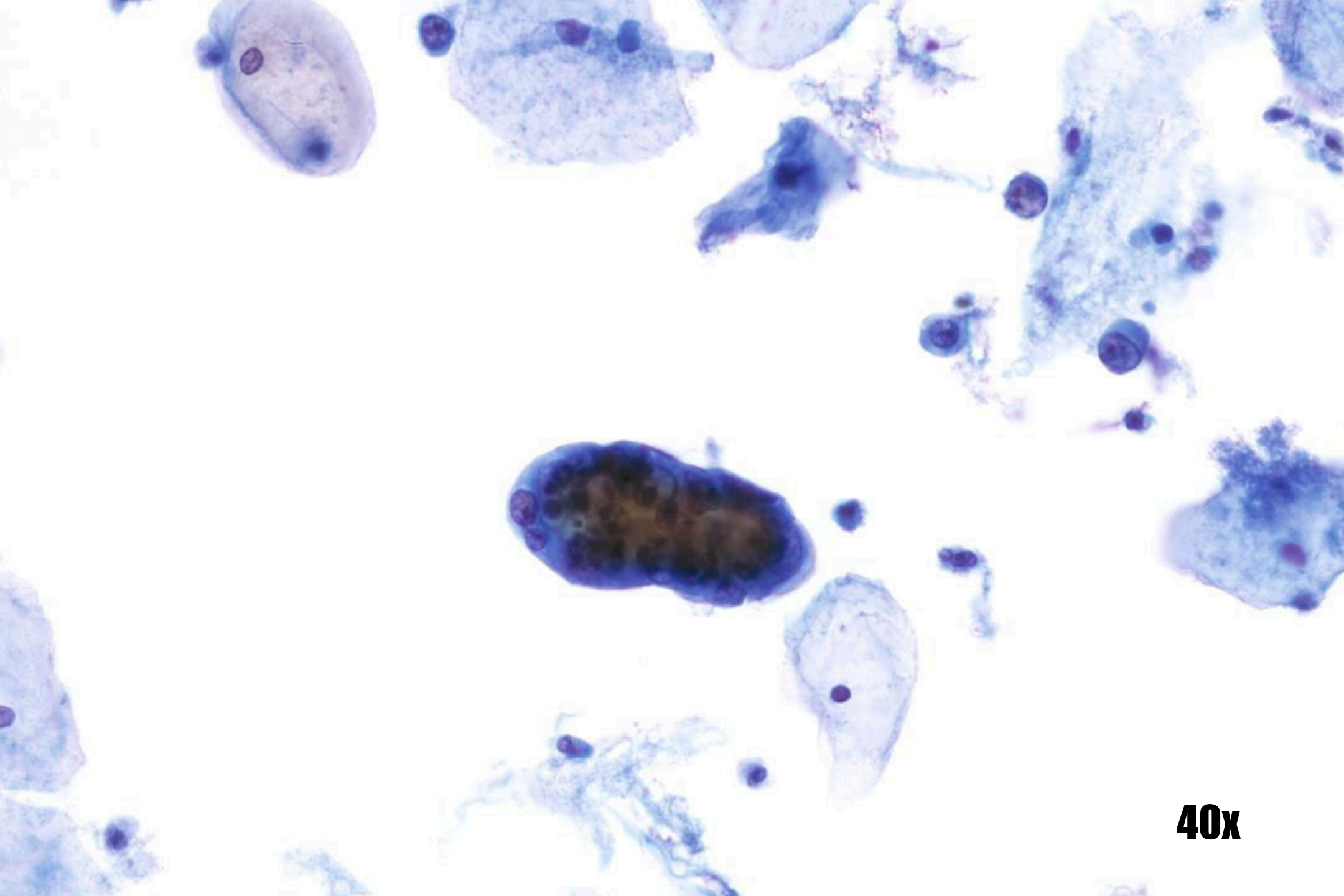
40x



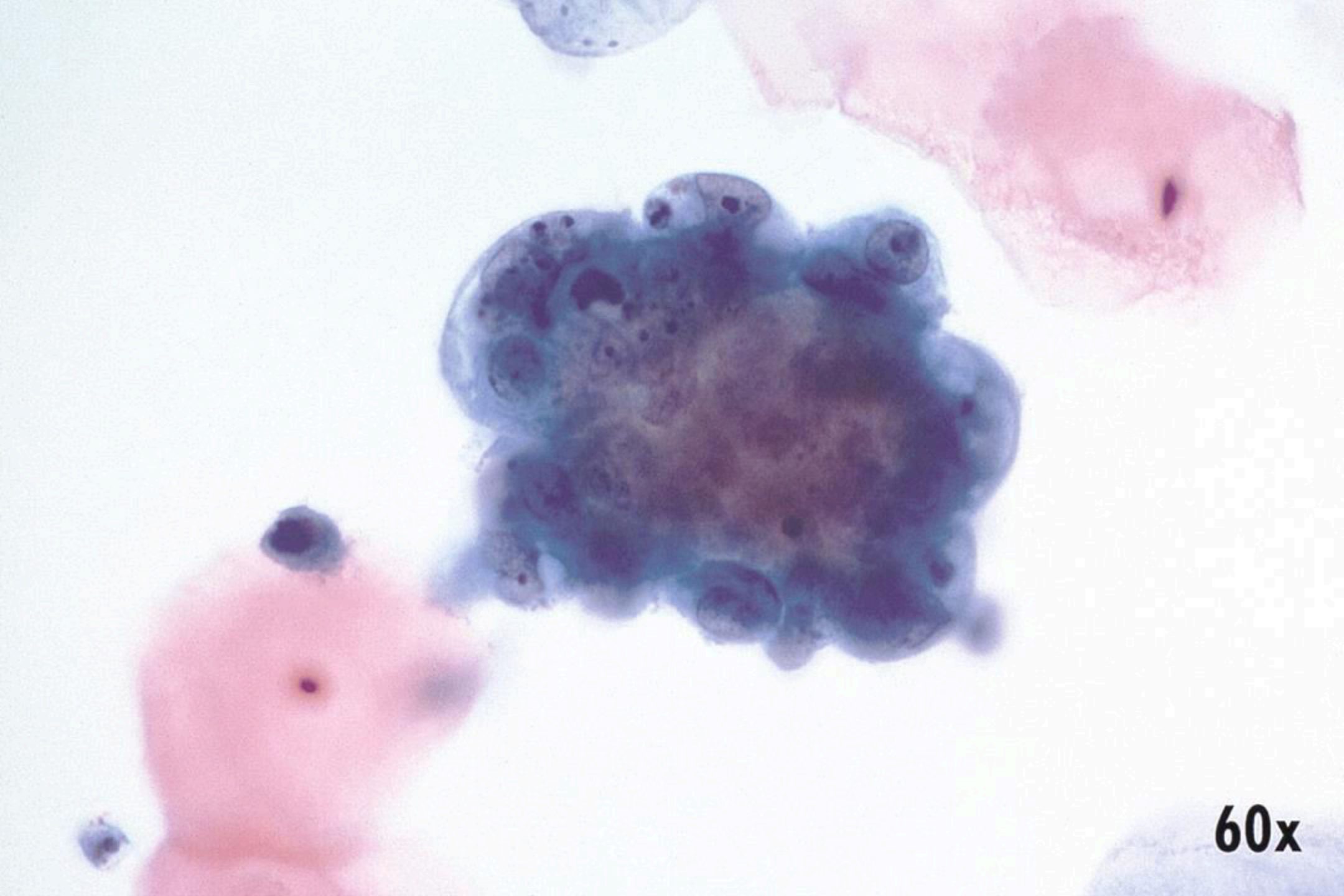
60x



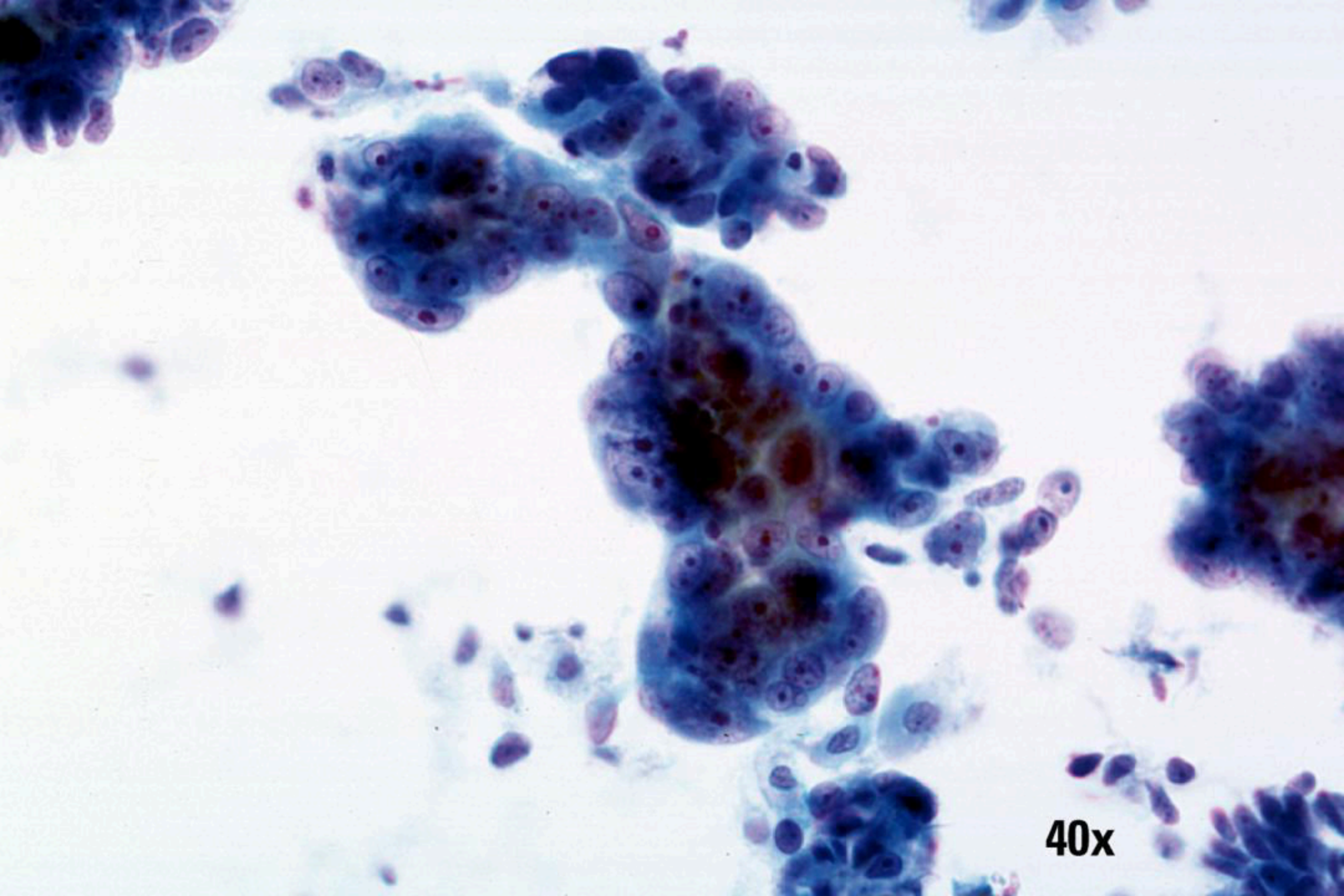
40x



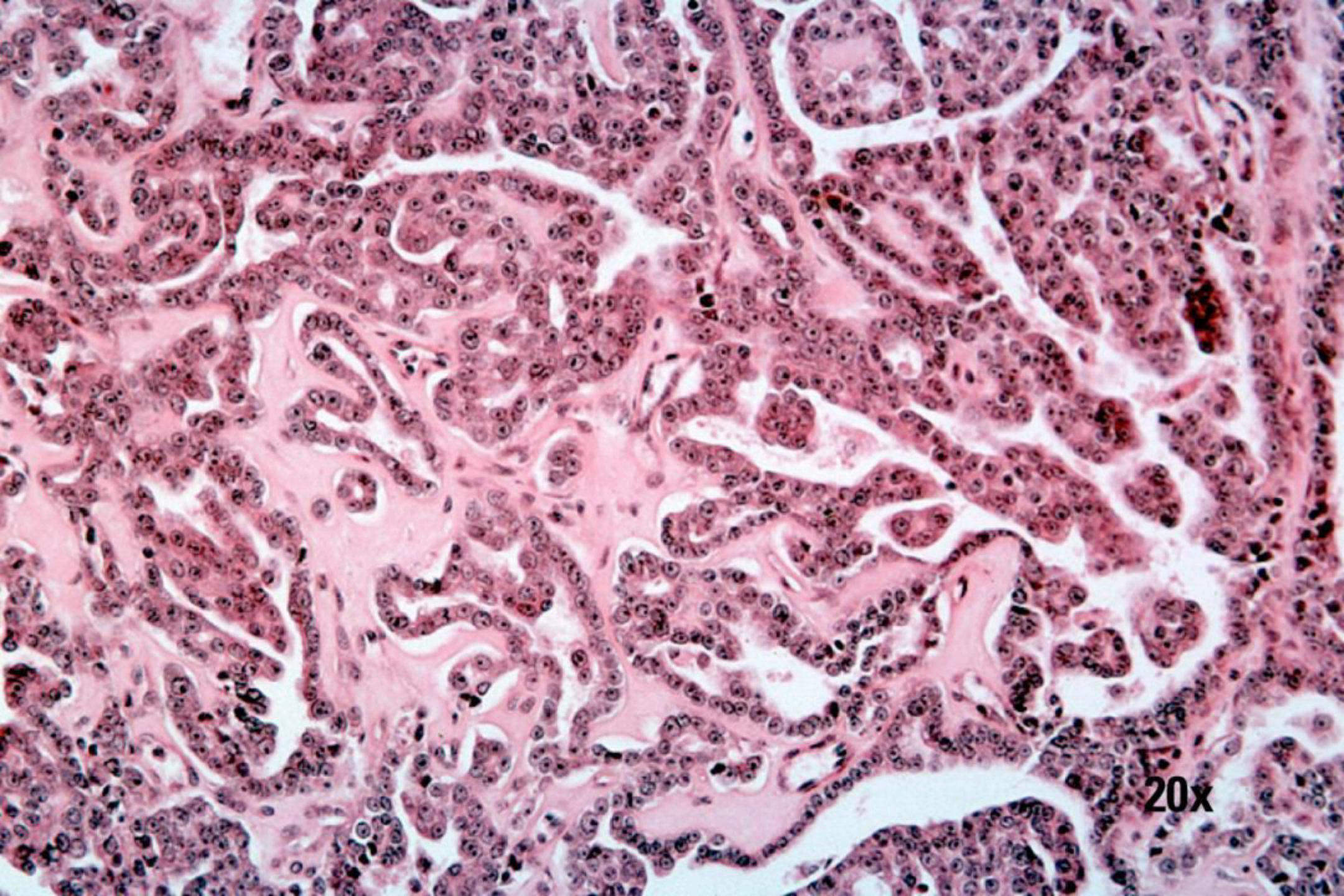
40x



60x



40x



20x

Einde Afwijkingen in epitheelcellen